

Clinical Application

Practical experience in using DIGITEX PRO (DAR-3000) for double-contrast esophagography



Dr. Akihiro Ino

Department of Clinical Radiology, Graduate School of Medical Sciences, Kyushu University

Akihiro Ino, Kenji Kawamoto, Kiyohisa Hiraka, Makoto Ueda, Kuoji Masuda
Department of Clinical Radiology, Graduate School of Medical Sciences, Kyushu University

1. Introduction

Realtime smoothed mask-digital subtraction (RSM-DSA) method by Shimadzu digital spot system DIGITEX PRO (DAR-3000) was developed for angiography. This imaging method discerns the difference in frequency components.^{1) 2) 3)}

This report relates practical experiences that we have gained from applying this imaging method to a double-contrast esophagography. As the application in this case is a non-vascular examination, we have named this method “Realtime Smoothed Mask-Digital Subtraction Radiography” (RSM-DSR).

2. RSM-DSR Principles

Conventional angiography subtraction relies on time-

interval difference to obtain target images. In contrast, RSM-DSR is a subtraction method that discerns the difference in frequency components of images. The frequency distribution in an esophagography comprises both low and high frequency domains. The low frequency domain typically has gradual density changes. The domain is made up of bone, soft tissue and air. On the other hand, the high frequency domain has sharp density changes. In the case of a barium-filled esophagus, the high frequency domain is composed of the contrast medium and the border areas of esophageal mucosa, bone and soft tissue.

With RSM-DSR, just the low-frequency domain from an image containing high and low frequency domain are subtracted to leave an image with just the high-frequency domain. The subtracted low-frequency image is known as a fuzzy-mask image and is created by adjust-

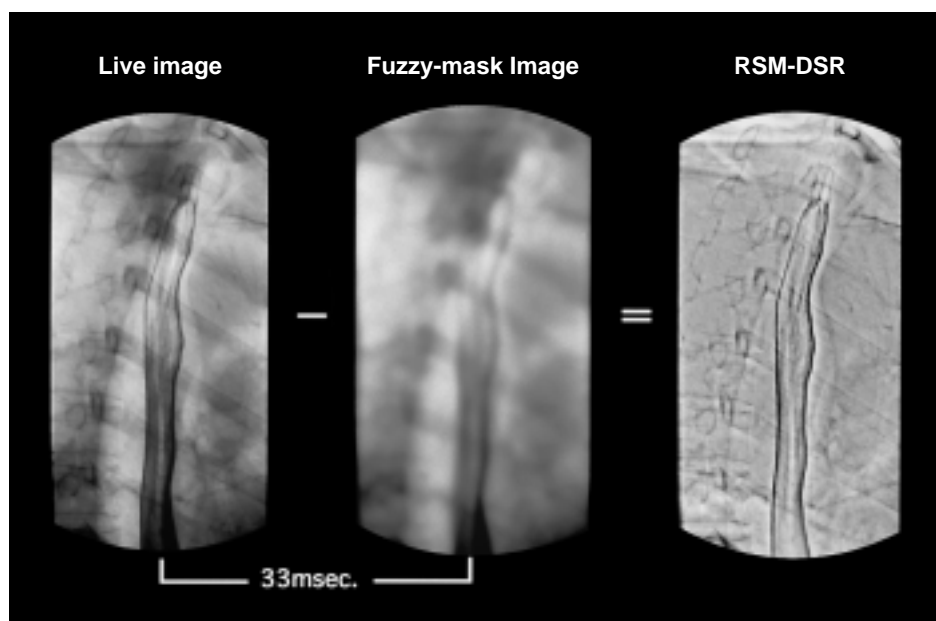


Fig.1 RSM-DSR principles

The far right RSM-DSR image is obtained by subtracting the center fuzzy-mask image from the far left live image. Live image is acquired in a mere 33msec after acquiring fuzzy-mask.

ing the internal electrode voltage of the image intensifier (I.I.). The RSM-DSR is obtained through a realtime subtraction process of this fuzzy mask image from the focused live image. **Fig1.** Shows the actual image processing.

The I.I. internal electrode voltage switches instantaneously in sync with x-ray radiation to enable acquisition of a live image in just 33msec after the fuzzy-mask image has been captured, which means that motion artifact due to breathing and body movement does not effect the image even if subtraction processing is performed. Consequently, continuous acquisition enables cine observation of RSM-DSR esophagus images. Furthermore, RSM-DSR allows image acquisition and moving of the I.I to track the barium flow at the same time.

3. Equipment

The devices used were a ZS-40 R/F table and a DIGITEX PRO (DAR-3000) digital spot imaging system, which are products manufactured by Shimadzu Corporation. The image acquisition modes available are digital spot, serial imaging and various type real-time DSA. The maximum acquisition frame rate is 7.5 frames per second. All imaging modes have 1024 x

1024 matrix spatial resolution and 12-bit (4096 gradation) density resolution. The RSM-DSR technique uses an RSM-DSA function that is one application of DSA imaging. The I.I. has multiple field sizes of 12, 9 and 7 inch; the 9-inch field size was used in all the imaging described in this report.

4. Optimum Condition Settings

First, an image was created using a high pass filter process to remove any low-frequency components in order to set the optimum conditions (I.I. internal electrode voltage) for obtaining the appropriate fuzzy-mask image (**Fig.2**). Taking into consideration factors such as presence of artifact and asperity in lesion areas that occur in the outer vicinity of border areas of the esophagus, it was judged that approximately 0.1Lp/mm of the low frequency components could be removed. Moreover, the optimum internal electrode voltage for this was 480V, so this was set as the optimum condition for RSM-DSR in esophagraphy.

5. Visual Evaluation of Image Quality

Four radiologists visually evaluated the image quality of RSM-DSR and live images in turn. The parameters that were investigated were the density uniformity of the

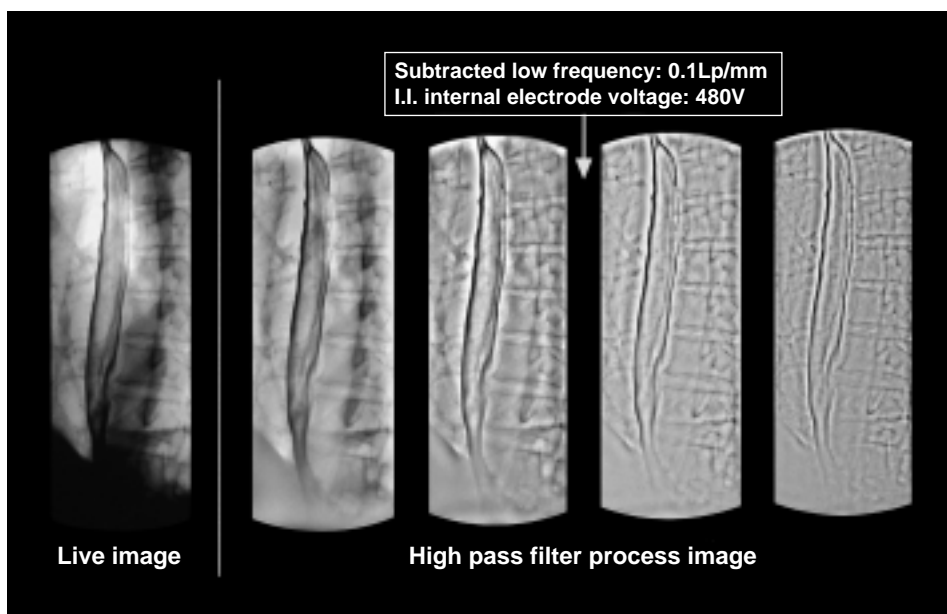


Fig.2 Optimum conditions for RSM-DSR
The image at the far left is the live image and the four images to the right have all had the low-frequency components removed using the high pass filter process. Desired information for the two images on the far right is lost due to excessive subtraction. Approximately 0.1Lp/mm is judged to be the best subtraction frequency for removing low-frequency components.

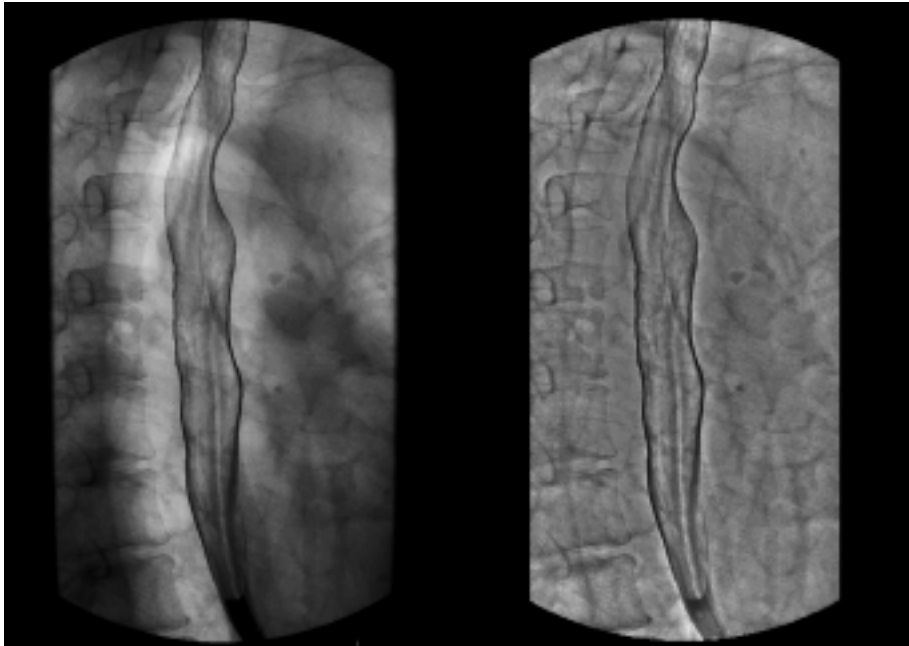


Fig.3 Normal esophagus
The image on the left is the live image and the one on the right is the RSM-DSR.

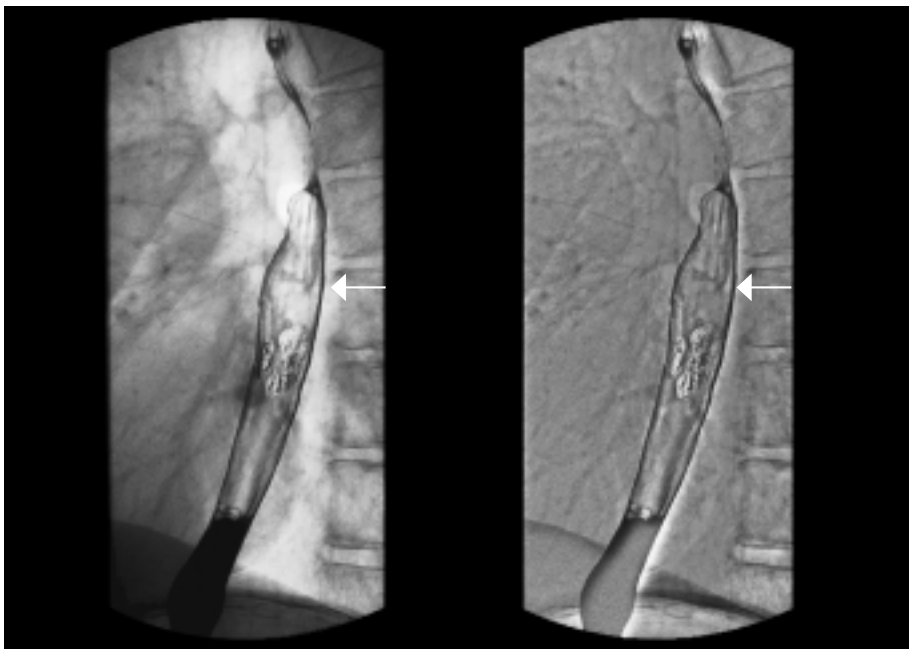


Fig.4 sm2 superficial cancer
The image on the left is the live image and the one on the right is the RSM-DSR. The arrows show that intra-epithelial evolution has gone as far as blocking the ligament.

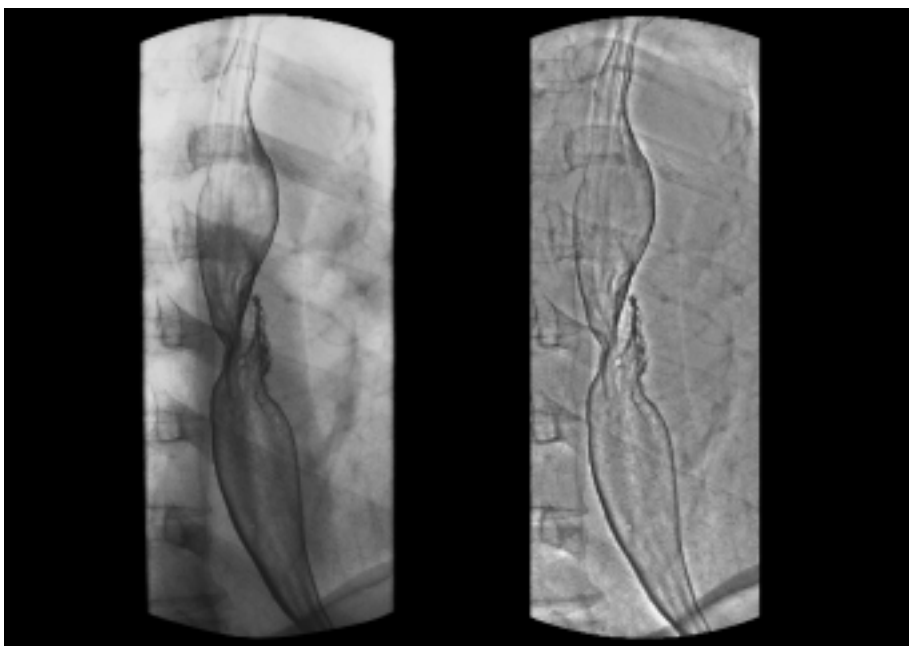


Fig.5 Type 3 progressive cancer
The image on the left is the live image and the one on the right is the RSM-DSR. The RSM-DSR is clearly superior as it provides uniformity of density.

whole esophageal mucosa and the existence, distribution and surface structure of lesions in the case of esophageal cancer in both normal and abnormal cases. **Fig.3** shows a normal esophagus. Uniformity of density of upper parts of the esophagus that overlaid with the lung, and lower parts of the esophagus that overlaid with the heart and blood vessels is clearly superior in the case of RSM-DSR. **Fig.4** shows an abnormal case of 0-IIc type superficial carcinoma at the sm2 depth of invasion. With regard to the distribution and surface appearance of the main lesions existing in the Mt region, the RSM-DSR is equal if not slightly superior to the live image.

The RSM-DSR produces a clearer image of the interrupted mucosal folds due to intraepithelial extension at the oral or anal side. Cine observation of this on a monitor after the examination enabled decisive diagnosis. **Fig.5** shows an abnormal case of type 3 advanced carcinoma. The RSM-DSR image is clearly more superior in showing the uniformity of density of the area where the oral side of the esophagus is overlaid by the lung. It is evident that the RSM-DSR also would identify with greater ease other lesions that might occur in this overlaid area. Barium often accumulates in the presence of advanced carcinoma, which hinders good illustration with conventional imaging technique (ie. non-RSM-DSR technique). But clear depiction of lesions in advanced carcinoma is possible using the RSM-DSR that produces clean double-contrast images.

6. Discussion

We were able to observe and select images on screen at any time directly after completion of imaging because we used the DIGITEX PRO (DAR-3000) - a digital spot imaging system manufactured by Shimadzu Corporation - that allows imaging at a top speed of 7.5 frames per second. For this reason, an increased radiation from having to retake due to bad timing in imaging is reduced. Notably, the DAR-3000 is extremely useful in the imaging of the esophagus. Also, thanks to the capability to subtract low-frequency components, images can be depicted with greater uniformity density for the whole esophageal mucosa than with conventional digital spot imaging (live images). This suggests that localized

diagnosis capacity of other lesions not noticed during examination and depiction capacity of the surface appearance of known lesions and lesion distribution are improved.

However, in the case of live images - that are the source images - RSM-DSR is not effective when there is an abundance of or poor deposit of barium. In some cases, tube insertion or steps to provide correct posture are required. In short, the radiologist still has to be extremely careful in double contrast imaging.

Application of RSM-DSR to the field of esophagrams has been suggested as being useful and will most likely contribute greatly to X-ray diagnosis of esophageal cancer - in particular, superficial carcinoma that requires collection of microscopic mucosal information. Moreover, this imaging method can be expected to have major practical applications in cancer diagnosis from now on because it can depict the whole of the esophagus in one imaging session.

7. Summary

- 1) The optimum conditions for RSM-DSR in double-contrast esophagography were as follows: I.I. internal electrode voltage of 480V (subtraction frequency of approximately 0.1 Lp/mm)
- 2) RSM-DSR provided superior depiction capacity beyond that of live image in all of the examination items. Notably, the RSM-DSR depiction of density uniformity and surface appearance of lesions was superb.

The above show that RSM-DSR has an excellent capacity for depicting the esophagus in the mediastinum that is composed of multiple different densities, which suggests that this method is useful for double-contrast esophagography.

Reference Contributions

- 1) Ichiro Sakamoto, Masashi Urano, Koken Matsuo et al: DIGITEX 2400 Practical Experience, MEDICAL NOW: 1995, 24: 12-15
- 2) Masumi Kawai, Shuji Tanaka, Takeshi Shiomi et al: Realtime Smoothed Mask DSA Method (RSM-DSA method) Development, Shimadzu Review separate volume: 1996, 53 (2): 107-116
- 3) Hiroshi Sawada, Hitoshi Kobayashi: About 3D-DSA Application "NaviDSA", MEDICAL NOW: 1997, 33: 16-17