

Our Experience Using the MobileDaRt Evolution for Neonatal Care



Dr. Hikaru Umezaki

Department of Pediatrics, International University of Health and Welfare Hospital
Director of NICU, Hikaru Umezaki

1. Introduction

Current advances in neonatal care not only include medical equipment designed for small infants, such as advances in incubators used to maintain infant body temperatures at a constant level and ventilators able to gently control respiration in even the lungs of newborns that weigh less than 1000 grams, but also clearly include major contributions from developments in drugs, such as artificial lung surfactants used to dramatically improve treatment of respiratory distress syndrome, which is the most common disorder facing premature infants with respiratory insufficiency. Because premature infants have insufficiently developed lungs and intestinal tracts, neonatal care primarily involves controlling respiration and providing nutrition via a feeding tube. Consequently, conventional X-rays serve an extremely important role at the NICU (Neonatal Intensive Care Unit), for diagnostics and selection of treatment method. However, as we have gained experience and better understanding of pathophysiology, the use of X-ray imaging has decreased due to concerns regarding radiation exposure. Furthermore, as the use of ultrasound examination equipment has become more widespread, conventional X-rays are no longer used as frequently. It now appears that examinations are mainly performed using ultrasound. Ultrasound examination systems have now become an essential tool in NICUs. That is probably because ultrasound enables immediately viewing still and moving images on-the-spot, which provides more bedside information than a single black and white X-ray image. In addition, treatment with artificial lung surfactants has made respiratory care far easier than before, so there is no longer the need to obtain multiple X-ray images of the lungs. What's more, in the field of neonatal care, it is left up to the neonatal physicians to read X-ray images. With radiography now being treated as an examination method of a previous generation, there are fewer doctors able to read chest and abdominal X-ray images properly. That has no doubt contributed to the decline of conventional radiography. Nevertheless,

even with better treatment methods and better medical equipment now available, when faced with an emergency, we are acutely reminded how conventional radiography still is extremely important for imaging. In particular, mobile X-ray systems required time for processing. Therefore, during an emergency, the time delay would make us feel impatient waiting for the images. That is why our hospital introduced a Shimadzu MobileDaRt Evolution unit (Fig. 1) equipped with a compact FPD, which enables obtaining images inside incubators, in our pediatrics department, when the NICU moved to a new building in April 2011. This has also been useful for neonatal care, as described in the cases below.



Fig.1 MobileDaRt Evolution

2. Examples of Using the MobileDaRt Evolution at Our Hospital

The center of perinatal care in Tochigi prefecture is the general perinatal care center for Jichi Medical University Hospital and



Fig. 2 International University of Health and Welfare Hospital

University Hospital. Our hospital, the International University of Health and Welfare Hospital (Fig. 2), is a regional perinatal care facility in northern Tochigi (Nasushiobara City) that processes about 4000 births per year with 9 NICU beds and 18 GCU beds. Our hospital transfers congenital heart disease and severe surgical cases to the general perinatal center, and mostly specializes in respiratory and circulatory care of premature infants.

Case 1 – Pulmonary Hypertension in Premature Infant

One big difference between premature infants and adults is that the lungs in premature infants are underdeveloped, requiring respiratory care for respiratory disorders that occur due to a lack of lung surfactant (respiratory distress syndrome). In the past, this required X-raying the chest to confirm respiratory distress syndrome or to confirm its severity. This was important for determining the infant's prognosis as well. However, now that administering artificial lung surfactant has been shown to provide dramatic improvement, it has eliminated the need to confirm the severity and has reduced the importance of chest radiography. In addition, treatment is currently started immediately after birth, without obtaining a chest X-ray image, so X-ray information is now used to confirm the position of the endotracheal intubation tube. However, in the case of this infant (Fig. 3), oxygenation did not improve even after administering the artificial lung surfactant. Therefore, we needed to quickly assess the lungs to determine the next course of treatment. The chest X-ray showed no problems in the lung field, so we decided to examine the heart with ultrasound, which resulted in diagnosing and treating the infant for pulmonary hypertension. Though urgency in this case was not especially great, it was important to determine whether the inadequate oxygenation was due to the lungs or heart and then treat it as quickly as possible. Without the chest X-ray, the ultrasound results alone would have been insufficient for diagnosing whether the artificial lung surfactant was effective in this infant, whether the tube was inserted in only one lung, whether a pneumothorax had occurred, and so on.

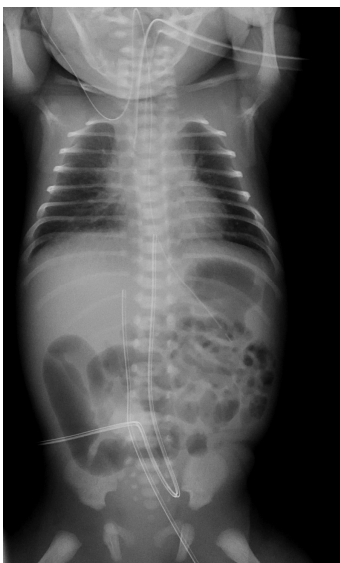


Fig. 3 Case 1

Case 2 – Pneumothorax

In this case, due to the poor respiratory status of the patient, intratracheal intubation and mechanical ventilation did not provide very much improvement.

By obtaining a chest X-ray, we were able to diagnose pneumothorax (Fig. 4) on the spot and treat the condition by thoracentesis. Though pneumothorax is also common in adults and this case was not a tension pneumothorax because its effects did not extend to the circulatory system. However, if it had been tension pneumothorax, it would have been important in terms of treatment to quickly determine whether the condition was on the left or right lung.

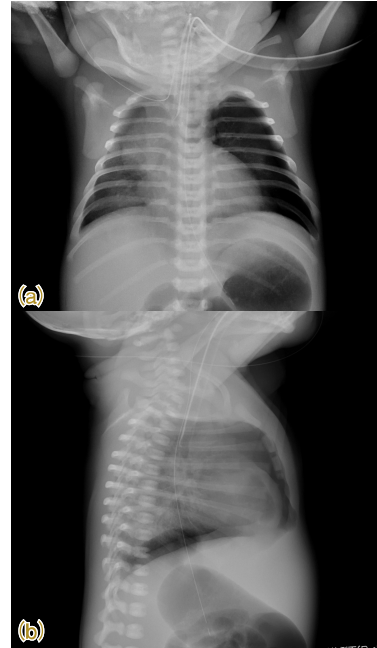


Fig. 4 Case 2
(a) Front (b) Side

Case 3 – Gastric Hemorrhage

This case was admitted to the NICU after sudden hematemesis two days after full-term birth. After attempting to stop the bleeding with internal medicine, the patient temporarily stabilized, but then suddenly went into shock, so we obtained a conventional abdominal X-ray (Fig. 5). It clearly showed a change from when the bleeding had stopped (Fig. 6). Due to the possibility of bleeding into the abdominal cavity, we had emergency surgery performed in the pediatric surgery department to save the patient. In newborns, gastric bleeding is usually due to a lack of vitamin K or bleeding from an acute gastric mucosal lesion, most of which can be treated by internal medicine. In the case of this infant, a gastric ulcer was discovered during surgery. In rare cases, it could have even caused a gastric rupture, so being able to quickly obtain an X-ray on-the-spot enabled saving the patient without subsequent complications. Of course, identifying pneumoperitoneum in an X-ray image can be effective for abdominal disorders in infants with a birth weight less than 1000 gram, which could cause necrotizing enterocolitis, intestinal perforation, or other perforation in the abdominal cavity, though I do not show X-ray images for these cases in this article.

However, the free-air in infants weighing less than 1000 grams is small and difficult to see. Based on our experience, this requires multiple X-rays. If this can be determined while the images are being obtained, then the patient can be moved to an appropriate position for imaging.

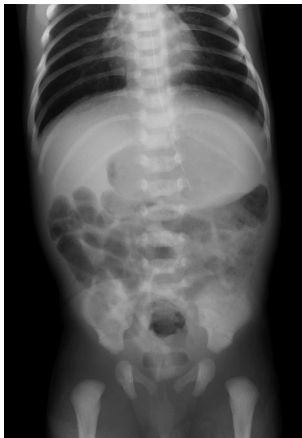

Fig. 5 Case 3A

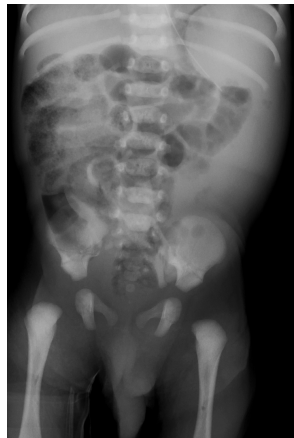

Fig. 6 Case 3B

Case 4 – Intrathoracic Tumor

This case did not have a high level of urgency, but it illustrates how a single chest X-ray can have significant consequences. In this case, an infant admitted for jaundice was observed to have a small hard protrusion on the precordial region since birth, so the attending physician obtained a chest X-ray, which revealed a suspected intrathoracic tumor on both sides (Fig. 7). Therefore, the case was transferred to the neonatal surgery department at a general perinatal center. Though we were hesitant to expose an infant without a significant respiratory disorder or thoracic deformity to the radiation from a chest X-ray, we felt it was worthwhile in this case, because of the difficulty in rendering chest cavity images adequately with an ultrasound examination.

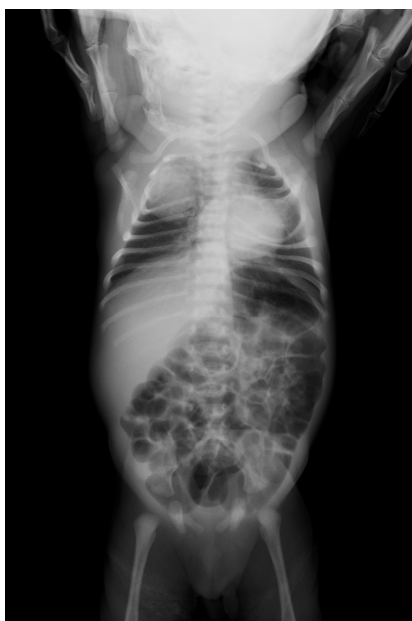

Fig. 7 Case 4

In addition to cases described above, radiography is also routinely used to confirm the position of catheter tips inserted percutaneously for intravenous hyperalimentation. However, when inserting the catheter into a newborn via an upper extremity, it can stray toward the head. Therefore, this previously required spending the time and trouble to obtain another X-ray if the tip location could not be confirmed in the first X-ray image. However, with the MobileDaRt Evolution, the catheter tip location can be confirmed on-the-spot, which avoids wasting the time of technologists and physicians.

Neonatal care involves treating infants weighing between 500 and 4000 grams, where infants with minor to extremely severe disorders are admitted to the NICU or GCU for treatment. Of these, chest and abdominal X-ray examinations are used for more severe cases. Therefore, it is important that results can be reviewed with as little time delay as possible. Perhaps this is not a good example, but presumably the reason digital cameras have become so popular is because they allow viewing images immediately. I think the same thing applies in clinical practice. Once immediately viewable X-rays become a matter of course, clinicians will not be able to return to conventional radiography methods requiring developing film before images can be viewed. No doubt, in a few years MobileDaRt Evolution units will be commonplace and we will tell younger doctors stories of how much harder we had it.

3. Summary

In neonatal care, X-rays were always an extremely important tool for examination, but they were a source of stress in urgent cases, because images were not immediately viewable. However, since the MobileDaRt Evolution allows verifying images on-the-spot, like a digital camera, it offers broad applicability even in urgent situations. Using an FPD has reduced the exposure dosage, but for neonatal and infant care applications, we wish that an FPD with even lower exposure levels were developed so that we could use X-rays more freely.