

Experiences Using the SONIALVISION G4 in the Field of Urology



Takeki Sugiyama, M.D.

Department of Urology, Nishiwaki Municipal Hospital
Takeki Sugiyama, Department Manager

1. Introducing the Hospital

Nishiwaki is a provincial city with a population of around 45,000 located slightly south of the center of Hyogo Prefecture. Nishiwaki acquired its name (meaning literally "west side") from being situated to the west of the Kakogawa River. Called colloquially "the bellybutton of Japan," banshu-ori textiles and fishhook production have thrived as local industries for many years, while Nishiwaki as it stands today is something of a peaceful, rural city where the main industry is agriculture though others like banshu-ori textiles do remain. Nishiwaki Municipal Hospital was established in March 1951 with the official title of the National Health Insurance-Administrated Healthcare Facility Nishiwaki Municipal Hospital as a relatively small hospital with only 47 beds and 5 medical departments. The following year, in April 1952, the region was organized under a municipal system of administration and the name was changed to Nishiwaki Municipal Hospital. With subsequent additions and improvements to medical departments and wards, by 1955 the hospital contained 197 beds. In 1970, the hospital became a general hospital with 230 beds, and by 1983 the hospital reached its present size with 320 beds.

2. The Department of Urology

For a long time the Department of Urology was a part-time post in the hospital, and obtained its first specialized full-time doctor from the Division of Urology, Kobe University in September 1974. Until recently, the department had performed medical care by a team of 3. I started working in the Department of Urology in April 2006, and since 2008 have held the position of department manager. At present, medical care is performed by a team of 2 (2 full-time doctors plus 1 part-time doctor). The hospital provides medical care over a wide geographic area, including the Tamba region

to the north (near Kaibara area) and all regions of north Kita-Harima (Miki, Kasai, Ono, Kato, and Nishiwaki). The department performs medical care 24-hours a day for all sorts of disorders, including urinary tract infections, urinary tract stones, and prostate gland enlargement, though it focuses on the diagnosis and treatment of malignancies.

The current hospital is an entirely new building of which construction started in March 2004 and its grand opening occurred in November 2009 (**Fig. 1**). In the new hospital, the patient records are digitized, and with each year the hospital has come to play an increasingly large role as a key hospital for the coordination of regional cancer treatment and as a support hospital for regional medicine. This has resulted in the services Nishiwaki Municipal Hospital provides becoming indispensable to northern Kita-Harima.



Fig. 1 View of Nishiwaki Municipal Hospital

In November 2013, nearby Miki City Hospital and Ono Municipal Hospital merged to become the Kita-Harima Medical Center. In one way, this merger became a test of the true abilities of Nishiwaki Municipal Hospital. Rare for regional hospitals of its size, our hospital now employs full-time doctors in almost all fields of medical care, including in pediatrics, obstetrics, and anesthesiology. Compared to the reductions in medical services being offered by hospitals in regional cities all over Japan,

Nishiwaki Municipal Hospital can be considered in relatively good condition.

The Department of Urology receives around 900 new male patients each year and around 500 new females patients, for a total of 1,400 new patients annually. Around 470 patients are admitted each year. Surgical procedures performed between January and December 2012 have included 28 total prostatectomies, 6 total cystectomies, 4 (open) nephrectomies, 12 (laparoscopic) nephrectomies, 65 TUR-BTs, and 93 ESWLs, all of which have been performed by 2 members of staff with support from 1 part-time outpatient doctor only on Wednesday.

The hospital was reviewed by the Japan Council for Quality Health Care (JCQHC) in June 2012, and obtained Ver. 6 accreditation with no issues. The part of the hospital that was most highly rated by the JCQHC was the "Hospital Power Project," an independent entity under the immediate control of the hospital director and run by the author of this article. In terms of medical care environment and patient services," the JCQHC designated Nishiwaki Municipal Hospital a model hospital and gave it a top rating. The "Hospital Power Project" regards the hospital as having not limited to the provision of medical care, and consists of a team that uses the latent capacities of volunteers to enact proposals made to the hospital administration, such as proposing art exhibitions, design proposals for invitation forms and business cards, proposed content and designs for the hospital website and public relations, measures for reducing medical costs, and proposals for the development of tools for nurses and doctors. The project has made a difference through the pursuit of unique activities such as establishing a childcare service within the hospital (November 2011) and an art exhibition of leading artists (a Japanese photographer in April 2011, and a French photographer in September 2011). We are driving for a higher level of awareness concerning how the hospital space is used, such as by having hospital staff take pride in the hospital and seeking to understand the role the hospital plays in the lives of local people. We understand these activities are very highly regarded. The message learned from these activities has been that while medicine must contribute to ensure the welfare and health of many people, after all, human resourcefulness and, by extension, the strength of the hospital is vital to this objective (Fig. 2).




Fig. 2 Photography Exhibition of a Leading Japanese Photographer, Herbie Yamaguchi

3. Introduction of the SONIALVISION G4

It goes without saying that in the field of urological medicine, every outpatient examination and procedure is important. The hospital block that contains the Department of Urology has 2 consultation rooms, an X-ray room that is independent from the central radiology block, an extracorporeal shock wave lithotripsy (ESWL) room, and a cystoscopic procedure room. The X-ray room in particular is used for a variety of procedures, including procedures that involve various types of endoscopic catheter placement and replacement such as the intravenous pyelogram (IVP), cystographic examination, and nephrostomy extension. The urological radiography system made by Toshiba that was in use for around 20 years since 1990 exceeded its serviceable life, and in 2012 a medical system purchasing (renewal) application was submitted to the hospital medical system and maintenance committee. As a result, in November 2013 a system selection committee meeting was held and after presentations from Shimadzu, Hitachi, and Toshiba, Shimadzu's SONIALVISION G4 (hereafter "G4") was eventually selected (Fig. 3).

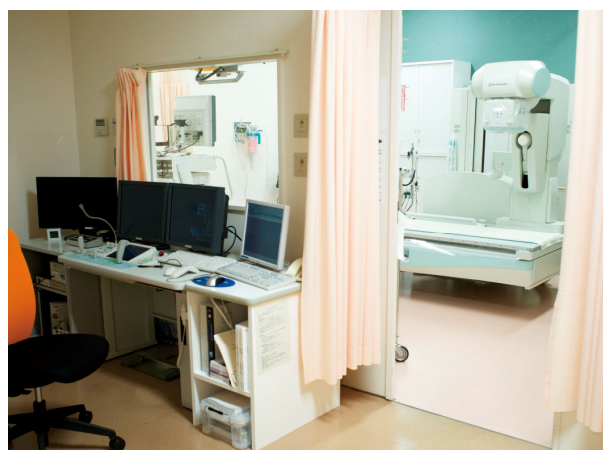

Fig. 3 Radiography Room at the Department of Urology

System selection was performed based on the specifications and selection criteria shown below.

- Excellent image quality
- An FPD is used.
- Excellent operability
- Due concern given to safety
- Excellent connectivity with an electronic patient record system
- Has a table device that can be used to perform special urological examinations.
- Wide imaging range on both sides of the table
- Provides a sufficiently large imaging range without moving the table.
- Table lowers as far as feasible to provide good patient access.
- Two or three LCD monitor screens at the tableside, of which one can be used to view images from the Olympus electronic scope that is exclusively used in the radiography room at the Department of Urology.
- Electronic patient record information, endoscopic images, and X-ray images can be displayed independent of one another, can be displayed as Picture-in-Picture (PinP), or can be tiled.

We visited nearby hospitals as well as Shimadzu's Kyoto Sanjo head office and evaluated the abilities of the system based on these selection criteria. The G4 was confirmed to meet almost all the requirements and was accordingly awarded the highest score. The distinctive features of each manufacturer were considered and after collecting competitive bids, we decided to use the G4.

4. Experiences Using the G4

After using the G4 for around 8 months, we learned the system has the following advantages.

- Ability to display endoscopic images and fluoroscopic images simultaneously makes ureteral stent replacements in particular much easier (Fig. 4).
- The wide imaging range on both ends of the table, particularly on the left side, means fluoroscopic images of the entire pelvic region can be obtained

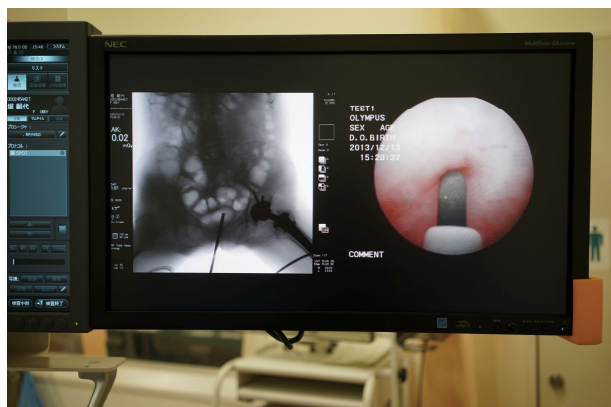


Fig. 4

even when using a leg support.

- The 17-inch FPD provides a very wide viewing range for fluoroscopic images, so examinations can be performed with minimal shifting of the FPD and without moving the table.
- A low minimum table height allows patients to get on and off easily and safely.
- We did not have wastewater duct work, but instead has a fluid receptacle that is appropriate for use with the cystoscopic back flow liquid waste system that uses disposable diapers and was conceived of by the nurses, which is very convenient (Fig. 5).
- Imaging quality is adjusted according to the urological examination, and is capable of capturing even pale calculus images.

Conversely, we perceived no disadvantages with using the G4, and the system left a very positive impression on X-ray technologists in terms of its operability, and on nurses who assist with patient positioning.

5. Case Example

- Patient: 52-year-old female
- Main complaints: Fever, lower back pain on left side
- Medical history: None
- Symptoms and examinations: Temperature of 36.4 °C on visiting the hospital; mild inflammatory response noted in blood tests with CRP of 6.2 and white blood cell count of 8,000. Pain on pressure found in left side of lower back.
- History of illness: The patient visited a local doctor with lower back pain on left side from two days prior. Left hydronephrosis was shown on ultrasound, etc. and the patient was given a referral for further examination and treatment.
- Image diagnosis: Calculus in the left ureter and associated hydronephrosis found on CT at another hospital

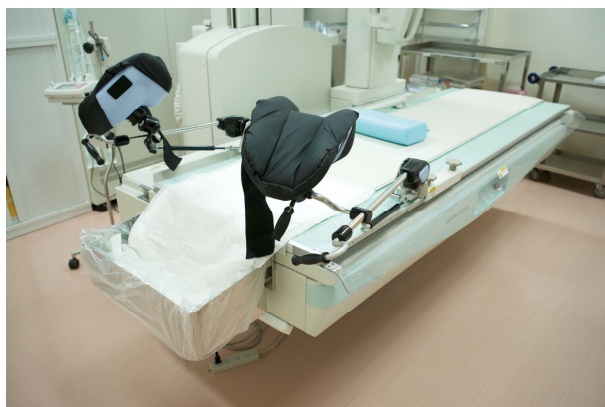

Fig. 5

In light of the above findings, ureteral calculus was diagnosed and ESWL scheduled. However, one week after the initial diagnosis, the patient presented with a fever of 39.4 °C in the night, and therefore received emergency consultation. The patient was diagnosed with pyelonephritis associated with calculus (**Fig. 6**). After admitting the patient, antibacterials were admitted to alleviate fever and provide pain relief, but by the following day fever remained and the patient's inflammatory response (CRP, etc.) was more intense, so a stent placement was determined necessary and immediately implemented. The stent was placed without particular incident (**Fig. 7**). From the following day her fever was alleviated, further 2 days later antibacterials were administered, and patient discharge occurred 6 days after admission.

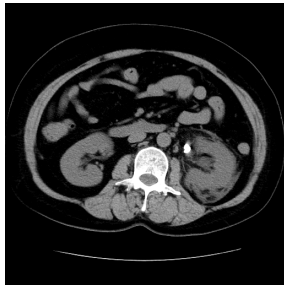

Fig. 6 CT Image

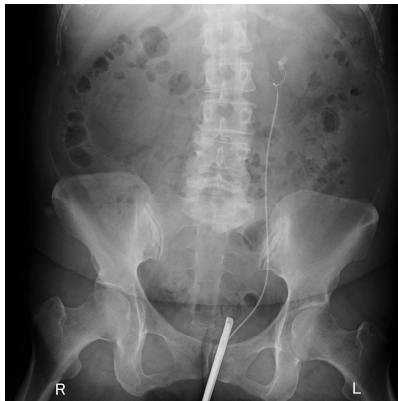

Fig. 7 KUB Image

The previous method of stent placement and replacement in cases such as this involved manipulating the catheter while alternating between viewing fluoroscopic images and endoscopic images. With the G4, these images can now be viewed simultaneously on the same screen, which allows

the doctor to concentrate on manipulating the catheter without having to change their line of sight and helps to shorten the duration of the procedure as well as increase its safety. While **Fig. 4** shows the fluoroscopic image and endoscopic image displayed alongside one another, main and subordinate relationship between displayed images, image size, and other parameters are completely customizable through configurable presets that can be loaded at any time during an examination, and is an extremely useful feature.

6. Conclusion

The role played by this core hospital in our regional city is growing year by year. This statement is particularly true with respect to local demands on our Department of Urology, and specifically the demands of the northern Kita-Harima medical district. Today's department of urological medicine must be capable of providing appropriate diagnosis and treatment not only for malignancies but for all sorts of disorders, including urinary tract infections, calculus diseases, and geriatric urological medical care. We regard the introduction of Shimadzu's G4 and its advanced functions for urological examinations and procedures to have created an environment where we are capable of providing more exacting diagnosis and treatment, and anticipate this difference to be exhibited fully.

Compared to general examinations, urological examinations and procedures are highly specialized and characterized by frequent use of endoscopy. Video is also used for urodynamic tests and the like. As all-purpose fluoroscopic examination system, the G4 has an extremely sophisticated FPD and a highly functional and useful table system capable of accommodating all the needs of urological examinations. Impressions to date have been without complaint. Image processing and connectivity with the electronic patient record system have been trouble free, and the diverse array of imaging processing features present in the standard system specification can be customized to suit medical care. In light of these factors, the G4 can without doubt be called a powerful examination system.