

Current Status and Future Possibilities of Gastrointestinal Tract Patency Evaluation Using Patency Capsules



Dr. Tepei Omori

Department of Gastroenterological Medicine, Tokyo Women's Medical University Hospital
Tepei Omori, Shinichi Nakamura, Keiko Shiratori

1. Background and Purpose

In Japan, gastrointestinal tract patency evaluations using patency capsules (PC) have been covered by health insurance since July 2012. This has expanded the range of diseases to which capsule endoscopy (CE) is applied. If the PC is not egested from the body, abdominal radiography is used to evaluate gastrointestinal tract patency but in many cases it is difficult to identify the PC position.

We have been investigating more accurate PC position evaluation method through PC experience in our hospital. This paper reports on our experiences using PC and on PC position evaluation by tomosynthesis.

2. About CE and PC

CE has been used as an examination method for clinical applications for about ten years. In Europe and in the United States, CE for the esophagus and large intestine, in addition to the small intestine, have been marketed and widely applied. Application of CE in Japan is entering its sixth year. Currently marketed capsule endoscopies are designed for the small intestine. Two types of device are used: the PillCam® SB Series manufactured by Given Imaging Ltd. and the Olympus endoCapsule®. The major features of capsule endoscopy are its low invasiveness and ability to perform safe examinations of the small intestine.

However, unlike in overseas, health insurance in Japan had covered only capsule endoscopy of the small intestine in cases of gastrointestinal bleeding of unknown cause. Its use in cases of other diseases had not been allowed.

The launch of the PillCam® SB2 plus in July 2012 expanded the range of targeted disorders to actual and suspected small intestine diseases in Japan. This permits application to scrutiny of intestinal

lesions in constrictive diseases with the potential for retention, such as definitively diagnosed and suspected Crohn's disease, after the risk of capsule retention—as a complication in capsule endoscopy—is eliminated by evaluating gastrointestinal tract patency using a PillCam® Patency Capsule. (Capsule retention is defined as retention of the capsule endoscopy in the body for two weeks or more, which may require surgical intervention.) See **Fig. 1**.





Capsule Endoscopy of the Small Intestine	
1 st . Generation CE (Pillcam SB1)  From 2007	<ul style="list-style-type: none"> View angle: 140° Frame rate: 2frame/sec±0.06% Battery operating time: 7±1 hours Size: Length 26mm, Width 11mm Weight: 3.45g <p>Health insurance covers: gastrointestinal bleeding of unknown cause</p>
2 nd . Generation CE (Pillcam SB2)  From 2010	<ul style="list-style-type: none"> View angle: 156° Frame rate: 2frame/sec±0.06% Battery operating time: over 8 hours Size: Length 26mm, Width 11mm Weight: 2.9g <p>Health insurance covers: gastrointestinal bleeding of unknown cause</p>
3 rd . Generation CE (Pillcam SB2plus)  From July 2012	<ul style="list-style-type: none"> View angle: 156° Frame rate: 2frame/sec±0.06% Battery operating time: over 8 hours Size: Length 26mm, Width 11mm Weight: 2.9g <p>Health insurance covers: confirmed or suspected intestinal disease + diseases with suspected constriction (including Crohn's disease)</p>
With Pillcam patency capsule  From July 2012	

Fig. 1

3. Intestinal Patency Evaluation

The PillCam® Patency Capsule (PC) has the same shape as the PillCam® SB2 plus, with dimensions of 26 × 11 mm. It is encapsulated in lactose containing 10 % barium sulfate (**Fig. 2**). The PC is ingested orally. If (1) egestion from the body by defecation is confirmed or (2) abdominal radiography confirms it has reached the large intestine, after 30 to 33 hours without change in shape, the risk of retention of the same-sized PillCam® SB2 plus is deemed extremely low, indicating that small intestinal examination by capsule endoscopy is applicable.

Approximately 30 hours after ingestion, intestinal juice start to permeate from both ends of the PC, causing it to be dissolved. After about five days,


only a thin coating film will remain. This eliminates the risk of PC retention that requires surgical intervention (Fig. 3).

However, in the actual clinical practice, it is often difficult to locate the PC position by using abdominal radiography.

PillCam® Patency Capsule

What is the PillCam® Patency Capsule?

In cases of known or suspected gastrointestinal strictures, the PillCam® Patency Capsule can be used to evaluate gastrointestinal patency prior to administration of the capsule endoscopy PillCam® SB2 plus.



Features of the PillCam® Patency Capsule

- Same size as PillCam® SB2 plus capsule
- Can be observed using radiography
- Dissolvable Capsule

© Capsule egested in original shape
 ○ Egested with no dissolved main body
 × Egested with dissolved main body
 × Completely dissolved—only the coating film is egested

Patency confirmed
 No patency

Fig. 2

Evaluation of Gastrointestinal Tract Patency

Evaluation Criteria for Gastrointestinal Tract (Small Intestine) Patency

Time Since Swallowing (T) Units: hours	Visual (Egestion)	Radiography	PillCam® Patency Capsule Position	Patency
T < 30	Confirmed*	—	—	Yes
30 ≤ T ≤ 33	Confirmed*	—	—	Yes
	—	Performed (in body)	Reached large intestine	Yes

—: N/A

Except for the cases “Confirmed Patency”, all other cases are judged to have no patency.

* Original condition: Disregarding any deformation of the PillCam® Patency Capsule timer plug, the condition that the egested PillCam® Patency Capsule has the same hardness as before swallowing, having no deformation of the main body.

Fig. 3

4. Experiences Using PC at This Hospital

In the period between July 2012 and the end of November 2012 we used PC to evaluate gastrointestinal tract patency prior to CE in 36 cases (33 cases of Crohn's disease, two cases of suspected small intestinal tumor, and one case of intestinal Behçet's disease). The position could be evaluated visually or by abdominal radiography in 63.9 % of cases. Conversely, positional evaluation (whether in the small intestine or large intestine) by abdominal radiography was difficult in 36.1 % of cases (Fig. 4).

Among these clinical cases where evaluation was difficult, in one case which we judged the PC was in large intestine, we experienced CE retention. The actual PC position was the narrowing of the terminal ileum and the CE was retained at this

constriction. In this case, stricture dilation was performed by double-balloon enteroscopy to recover the CE (Fig. 5 and Fig. 6).

In cases where the positional evaluation was difficult, the PC tended to be located in the pelvic cavity. At this hospital, we used additional abdominal radiography (lateral or lateral recumbent) and abdominal ultrasonography in such cases but this often did not lead to a definitive judgment of the positions.

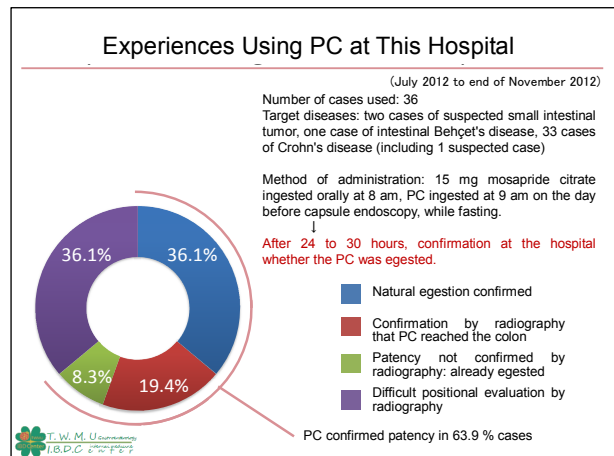


Fig. 4

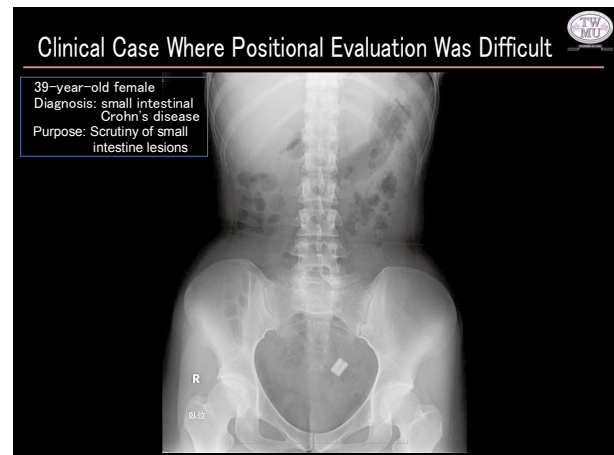


Fig. 5

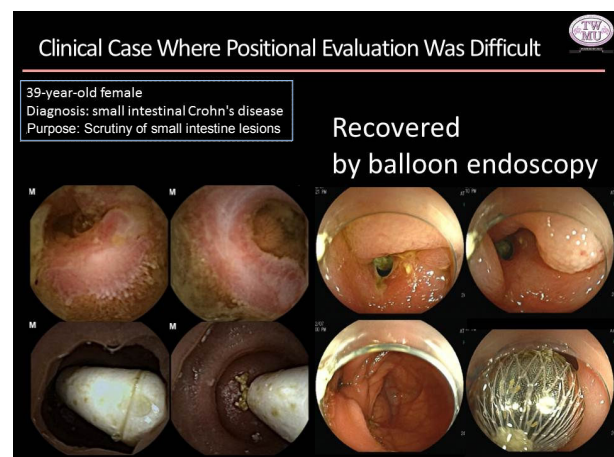


Fig. 6

5. Issues of Patency Evaluation by Abdominal Radiography

We believe that the structure of the abdominal cavity is related to the difficulties in identifying the PC position by abdominal radiography. The small and large intestines are compressed within the restricted space inside the abdominal cavity and the morphological information on soft tissues overlaps in abdominal radiographs, making identification of the PC position difficult (Fig. 7 and Fig. 8). Using CT makes positional identification easier but this procedure should not be taken without paying attention to X-ray exposure dose and medical expenditure.

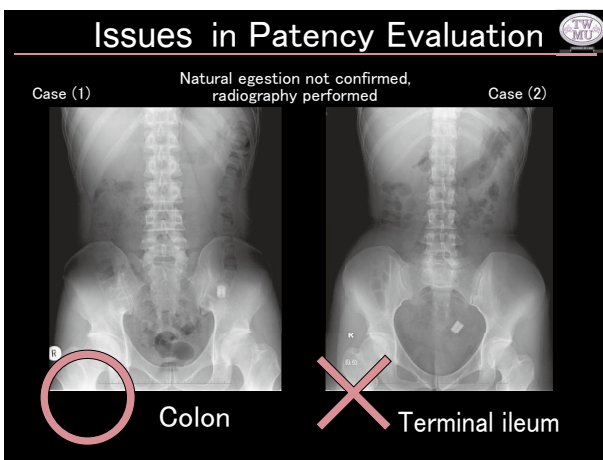


Fig.7

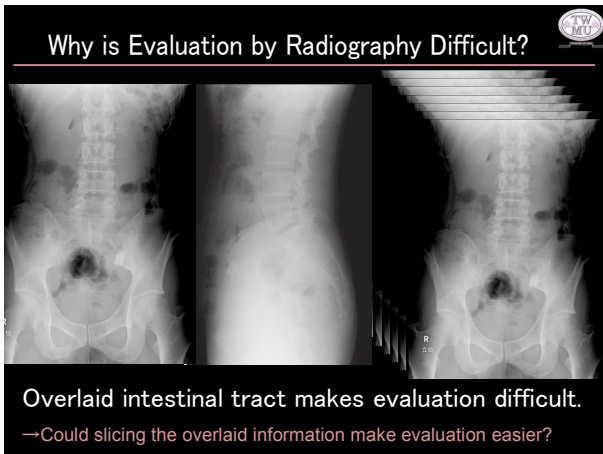


Fig.8

6. Patency Evaluation by Tomosynthesis

Wondering if slicing up the overlaid morphological information would permit positional evaluation of PCs, we used tomosynthesis on the abdominal soft tissue. One of the cases is introduced here. In the abdominal radiograph, the PC is located on the left side of the pelvis, making positional

evaluation difficult. However, the tomosynthesis images which were taken at almost the same time as radiography showed the path of the colon clearly and the PC was identified in the sigmoid colon (Fig. 9). Other tomosynthesis images show the paths of the ascending, transverse, and descending colons (Fig. 10), suggesting that the PC position should be identified at other locations in the large intestine.

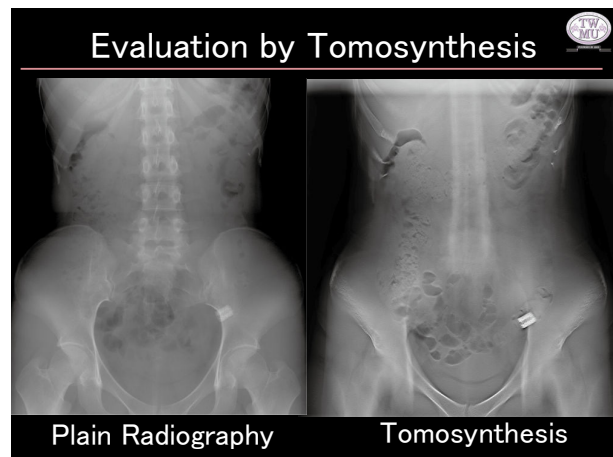


Fig. 9

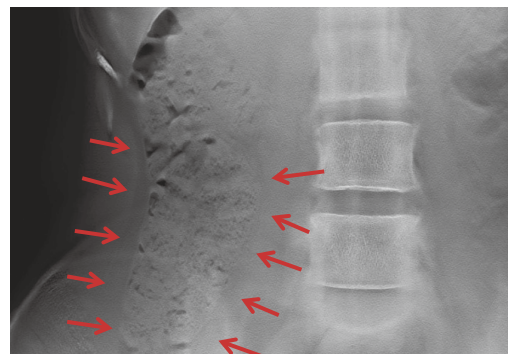


Fig. 10(a) Ascending Colon

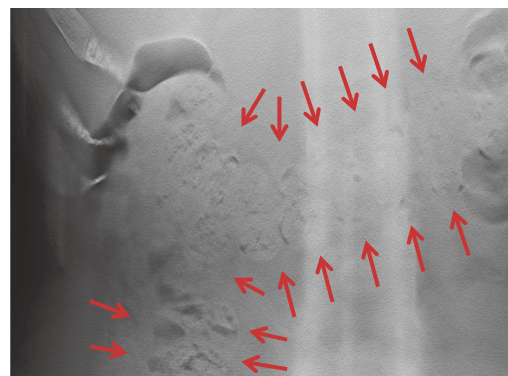


Fig. 10(b) Transverse Colon

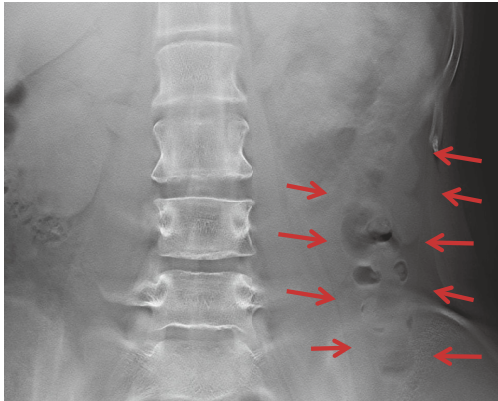


Fig. 10(c) Descending Colon




Fig. 10(d) Sigmoid Colon and PC

7. What Is Tomosynthesis?

Tomosynthesis takes multiple projection images in a single tomographic imaging operation and applies post-processing to reconstruct section images at the required depths. Tomosynthesis is less invasive; it requires approximately twice the X-ray exposure dose of plain radiography and one-tenth the dose for CT. Tomosynthesis is the promising low dose X-ray imaging method for evaluation of PC locations.

8. Conclusions

We reported the current situation and future possibilities for evaluating gastrointestinal tract patency using patency capsules. This is the first report using tomosynthesis for the patency evaluation of PC in gastrointestinal tract, and we will continue further investigations in the future.