

# Application of Tomosynthesis for Colon X-Ray Examination

Department of Radiology, Fussa Hospital  
**Takashi Nonaka**



Mr. Takashi Nonaka

## 1. Introduction

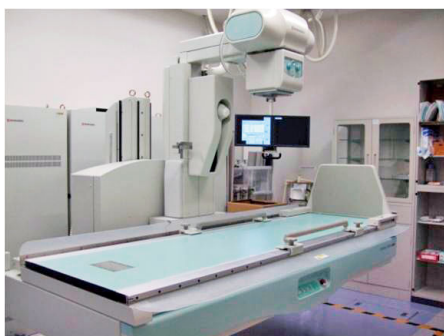Fussa Hospital is located in the western part of the Tama region of Tokyo. It functions as a general hospital with 316 beds and provides health care to local and regional communities.

The Department of Radiology has 12 full-time medical X-ray technologists and two full-time radiologists, who perform CT, MRI, various types of radiography, contrast examinations, image diagnosis, nuclear medicine examinations, as well as therapy, radiation therapy and IVR (**Fig. 1**).



**Fig. 1** External View of Fussa Hospital

The hospital was reopened in October of 2008 after renovations that saw the introduction of FPD systems in the majority of its image diagnosis systems (three general radiography systems, two fluoroscopy systems, one mammography system, one mobile X-ray system, and one angiography system). Of these systems, two of the fluoroscopy systems are Shimadzu SONIALVISION safire series, and used to perform various types of fluoroscopy examinations. One of these units is equipped for tomosynthesis and slot radiography (**Fig. 2**).



**Fig. 2** SONIALVISION safire Series

At Fussa Hospital, fluoroscopy examinations are used in a wide range of clinical departments, including surgery, orthopedics, urology, pediatrics, obstetrics and gynecology, and internal medicine. In these departments, the vast majority of examinations are surgery-related (including vascular system IVR), with two fluoroscopy systems fully utilized for this purpose.

## 2. Background

Although colorectal cancers in Japanese people were once thought to be relatively rare, they are among a number of cancer types for which rates of incidence have been increasing rapidly in recent years in Japan. After gastric cancers and lung cancers, by 2020 colorectal cancers are anticipated to account for the highest incidence in number of cases and rate of incidence of all cancers in Japanese men and women combined. The number of deaths due to colorectal cancer has more than doubled in the last 20 years and continues to increase, with colorectal cancers being particularly prevalent in Japanese women among whom it is the primary cause of cancer death.<sup>1)</sup>

Fussa Hospital performs a very large number of surgical procedures, surgery-related examinations and treatments, with many of these procedures pertaining to lower gastrointestinal tract.

Among those procedures, colon X-ray examinations are performed preoperatively as a matter of course, as well as for the purpose of medical examination.

When a colon X-ray examination is performed at Fussa Hospital, after routine radiography has been performed, three further overall images of the colon are taken in standing, supine, and prone positions.

These images are used to help in examining the entire colon in terms of positional and morphological matters, and are also requested by the gastrointestinal specialists who perform surgery. The 17-inch field-of-view of the SONIALVISION safire series allows observation of a wide area (**Fig. 3**).

There are also the significant benefits of being able to acquire tomographic images of the entire colon (Fig. 4).

Here is reported a study of the current and potential applications of tomosynthesis with the SONIALVISION safire series for colon X-ray examinations.

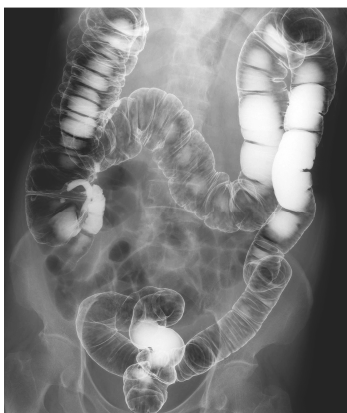

Fig. 3

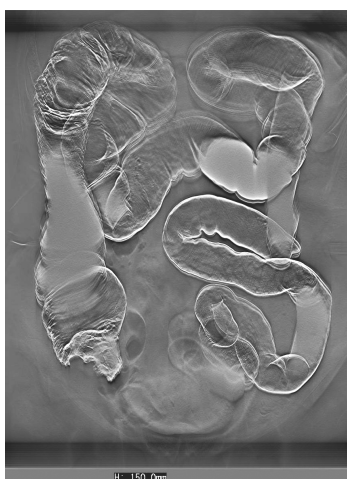

Fig. 4 Tomosynthesis Image with 17 × 17 Field-of-View

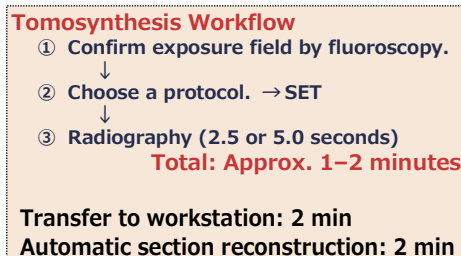
### 3. Tomosynthesis

Previous tomography required significant time and effort to produce the images, and a lack of continuity between the tomographic images increased the number of scans required to observe a given sectional plane image, placing a large burden on the patient both in terms of time and exposure dose.

Using tomosynthesis, the data acquired with a single scan can, after applying filtered back protection (FBP) (a method of reconstruction commonly used in CT that creates high-contrast and sharp images with few artifacts by assuming cone-beams to be approximately parallel beam scans) and shift-and-add (SA) (determines a sectional plane by matching a conventional plain tomographic image down to individual pixels with the amount of movement and shifts their positions accordingly. SA has the demerit of producing significant artifacts, but creates images close in quality to those obtained with previous film section imaging) algorithms, produce a reconstructed

image of any section in the area scanned with high spatial resolution. The workflow and parameter settings for tomosynthesis are shown in Table 1.

When parameter settings are programmed and ready to use, the imaging itself takes around 1–2 minutes and to obtain the tomographic images takes a further 4 minutes. Operation of the systems involved is very simple, and the minimal examination time means there is little burden on the patient.



Tomographic Angles	40°, 30°, 20°, 8°
Tomographic Pitch	0.5, 1, 2, 3, 5, 10, 15, 20, 25 mm
Range of Section Reconstruction	0–250 mm
Tomography Time	Fast: 2.5 sec
	Slow: 5.0 sec
Acquisition Rate	High Res.: 15 fps
	Normal: 30 fps
Reconstruction Mode	Shift-and-add (SA)
	Filtered back projection (FBP)

Table 1 Tomosynthesis Workflow and Each Parameter Setting

### 4. Study Methods

To determine the optimum conditions for radiography and reconstruction, items (1) to (5) below were studied.

(1) Measuring the effective section thickness  
 Metal beads were used to measure the effective section thickness for each swing angle and each reconstruction filter. ImageJ was used to perform the analysis, and the full width at half maximum was measured from the profile of the metal bead from which an effective section thickness was calculated (Fig. 5).

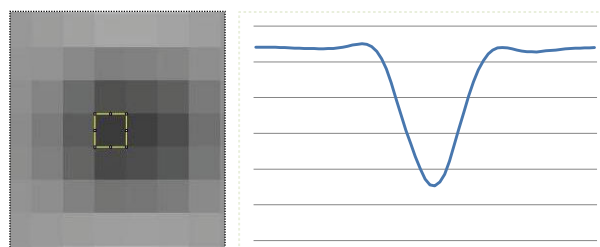


Fig. 5 Measuring the Effective Section Thickness

(2) Unique acrylic tube phantom evaluation  
 A unique acrylic tube phantom was used to investigate the ability to render an image with differing swing angles and reconstruction filters. The acrylic was interlaminated and images were obtained in the directions shown in Fig. 6. The evaluation was made based on the profile curve.

### (3) Measuring the exposure dose

The surface dose was measured at different acquisition speeds (slow or fast) and swing angles (8°, 20°, 30°, 40°).

### (4) Evaluating rendering ability using a unique imitation colon phantom

A unique imitation colon phantom (hereafter colon phantom) was used to evaluate rendering ability in various ways (Fig. 7).

(5) Exposure dose was measured at various tube voltages (80–120 kV) and rendering ability was evaluated (colon phantom) with the purpose of reducing the exposure dose.

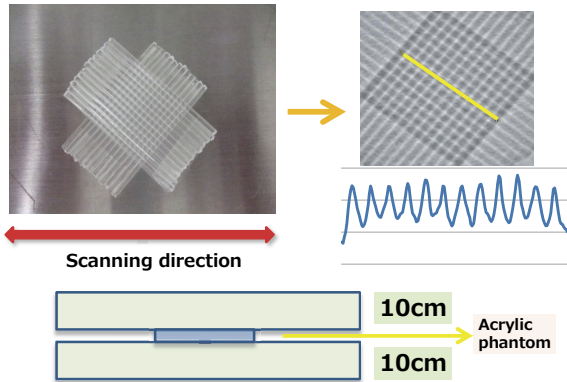
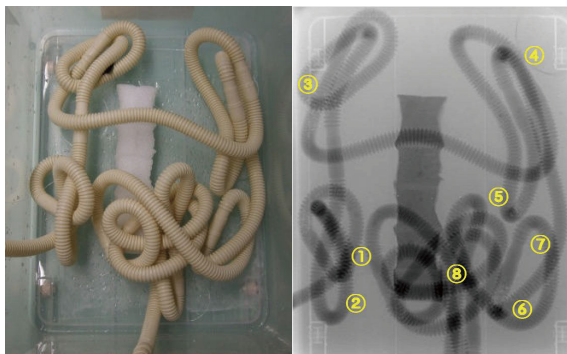


Fig. 6 Evaluation Using an Acrylic Tube Phantom



- |  |                                      |   |
|--|--------------------------------------|---|
| <b>Matters evaluated</b>               |                                      | <b>Evaluation scores</b><br><ul style="list-style-type: none"> <li>• Good: 4 points</li> <li>• Slightly poor : 3 points</li> <li>• Partially poor : 2 points</li> <li>• Poor (indistinguishable) : 1 point</li> </ul> |
| ① Imitation ileocecum tumor group      | ⑥ S-D J tumor group                  |   |
| ② Extent of ileocecum overlap          | ⑦ S-D J tumor rendering              |   |
| ③ Rendering of a hepatic flexure tumor | ⑧ Tracing along the colon sigmoideum |   |
| ④ Extent of splenic flexure overlap    | ⑨ Graininess                         |   |
| ⑤ Splenic flexure tumor group          | ⑩ Contrast                           |   |

Fig. 7 Evaluation Using a Colon Phantom

## 5. Results

(1) Effective section thickness measurements are shown in Table 2.

The effective section thickness became progressively thinner as the reconstruction filter transitioned from "+ +" to "- -".

No major difference was observed between using swing angles of 40°, 30° and 20°. At a swing angle of 8°, the section thickness was thicker relative to the other angles.

Reconstruction Method	Swing Angle (°)	Reconstruction Filter	Section Thickness (mm)
FBP	40	Thickness ++	12.5
		Thickness +	9.5
		Thickness +-	7.5
		Thickness -	6
		Thickness --	4.5
	30	Thickness ++	12
		Thickness +	10
		Thickness +-	8
		Thickness --	5
	20	Thickness ++	12.5
		Thickness +	9.5
		Thickness +-	8.5
		Thickness -	6.5
		Thickness --	5.5
	8	Thickness ++	15
		Thickness +	12.5
Thickness +-		11.5	
Thickness -		10.5	
Thickness --		10	

Table 2 Effective Section Thickness Measurement Results

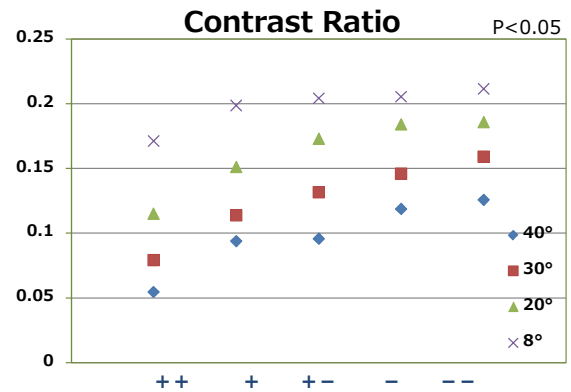


Fig. 8 Acrylic Tube Phantom – Contrast Ratio Plot

(2) Contrast ratios measured during evaluation of the acrylic tube phantom are shown in Fig. 8.

The contrast ratio was at its highest when the swing angle was 8° and with a reconstruction filter of "Thickness - -".

(3) Results of measuring the exposure dose are shown in Table 3.

Since the set acquisition speeds are 2.5 seconds on fast and 5.0 seconds on slow, the surface exposure on slow is double that on fast. No difference could be seen when varying the swing angle since when imaging is performed, the tomography time is matched to the angle (exposure on fast is for 2.5 seconds and exposure on slow is for 5.0 seconds, regardless of the angle).

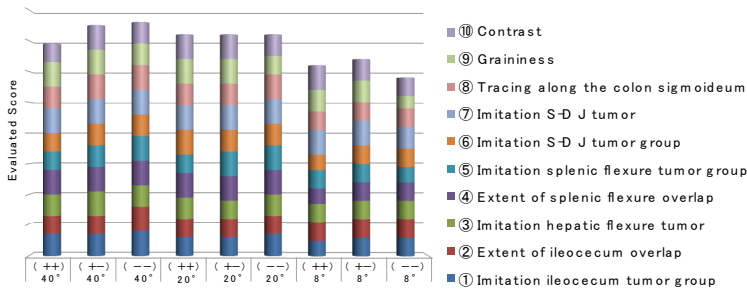
Acquisition Mode	Acquisition Speed	Swing Angle (°)	Surface Exposure (mGy)
HighReso	SLOW	40	7.02
		30	7.22
		20	7.12
		8	7.05
	FAST	40	3.68
		30	3.49
		20	3.42
		8	3.59

Table 3



(4) Results of the colon phantom evaluation are shown in **Fig. 9**.  
 A large swing angle resulted in good rendering ability and a "- -" reconstruction filter also resulted in good rendering ability, but with strong contrast and excessive accentuation of edges that affected the ability to render the imitation tumor (**Fig. 10**).  
 (5) Results of measuring the exposure dose at differing tube voltages are shown in **Table 4**, and an


evaluation of rendering ability is shown in **Fig. 11** (swing angle: 40°, reconstruction filter: "+ -").  
 Although this is an obvious relationship, when the mAs level was reduced, the surface dose also reduced. There was no major difference in ability to render the colon phantom at tube voltages of 80 kV or higher. There was also no significant difference in the standard deviations calculated. Tomosynthesis images of the colon phantom are shown in **Fig. 12**.



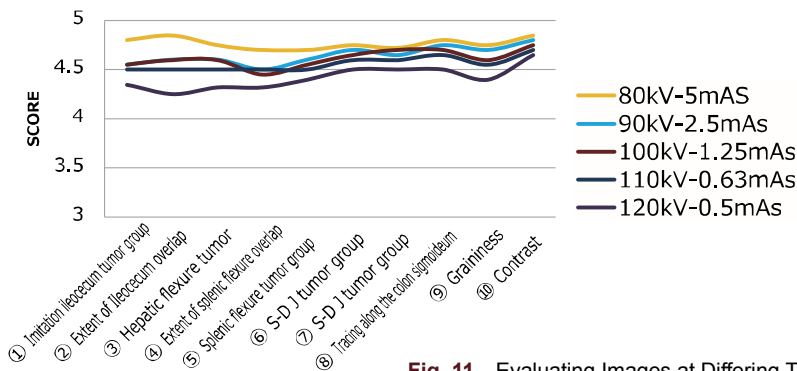
Tube Voltage (kV)	mAs Level	Surface Exposure (mGy)
80	5	13.96
90	2.5	9.583
100	1.25	6.226
110	0.63	3.675
120	0.5	3.48

**Table 4**

**Fig. 9** Results of the Colon Phantom Evaluation




**Fig. 10** Colon Phantom Images



P<0.05

Tube Voltage (kV)	mAs	Standard Deviation (SD)
80	5	586.179
90	2.5	622.143
100	1.25	612.982
110	0.63	604.092
120	0.5	594.872

**Fig. 11** Evaluating Images at Differing Tube Voltages



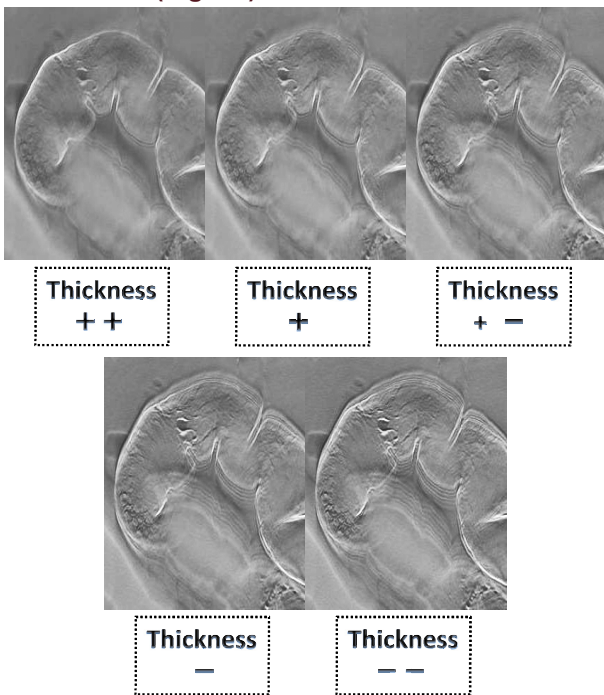
**Fig. 12** Evaluation at Differing Tube Voltages Using the Colon Phantom

## 6. Discussion

Regarding the effective section thickness, the tomosynthesis reconstruction filter includes a low-pass filter that limits bandwidth. Section thickness is varied by increasing or reducing the strength of the bandwidth limitation. A setting of "Thickness ++" creates a strong limitation on bandwidth and increasing the section thickness, while "Thickness --" creates a weak limitation on bandwidth that reduces the section thickness.

We were able to achieve good rendering of even very small shadows by using the appropriate reconstruction filter with the colon phantom.

Based on this study, a swing angle of 40° and the reconstruction filter "+ -" was optimum in terms of rendering ability and artifacts for a colon X-ray examination (Fig. 13).



**Fig. 13** Deference in Rendering Very Small Polyps Using Different Reconstruction Filters

With this type of examination, movement can also cause artifacts, so it is important to choose an acquisition speed (slow or fast) according to the status of the patient.

There are concerns that tomosynthesis increases the exposure dose to patients, but by increasing the tube voltage and reducing the mAs level, it is possible to reduce the exposure dose to that of conventional colon X-ray examinations. In this study, no significant difference in rendering ability was observed between different tube voltages when using the colon phantom, and we believe 100 kV or higher high-voltage radiography to be clinically useful. Fig. 14 shows a workflow comparison for performing intestinal infusion without tomosynthesis, and after introducing the technique.

Total times of one tomosynthesis are 1-2 minutes and performing tomosynthesis does not adversely

affect imaging times.

Tomosynthesis can be used to recognize lesions as well as create an image of the entire colon, reducing the risk of overlooking any clinical problems.

Clinical images are shown in Fig. 15. An elevated lesion can be seen in the colon sigmoideum, which is overlapped by the rectum on the image. Using tomosynthesis allows the area of this lesion to be rendered clearly.

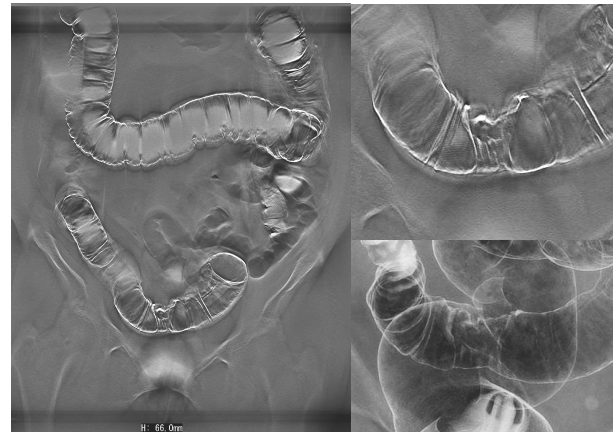
The X-ray parameters are 100 kV and 1.25 mAs, which is high-voltage radiography but after a clinical assessment we believe this will pose no problems clinically.

An elevated lesion is observable in the SD junction in Fig. 16, while the small polyp in the colon sigmoideum was not observed by fluoroscopy. The elevated lesion and small polyp were easily observable using tomosynthesis.

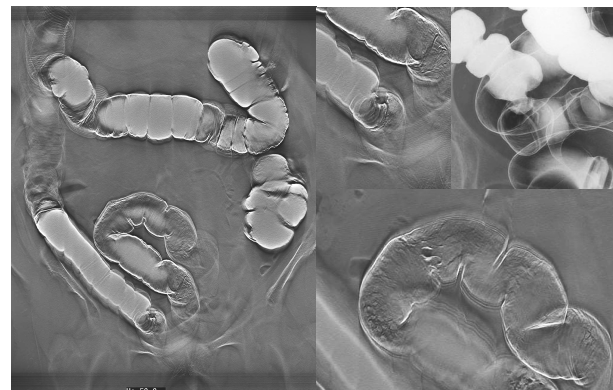
X-ray parameters are 110 kV and 0.63 mAs.

	Previous Method	With Tomosynthesis
From Rectum to Colon Sigmoidum	6 to 8	6 to 8
Descending Colon	2	2
Splenic Flexure	2	2
Transverse Colon	2	2
Hepatic Flexure	2	2
Ascending Colon	2	2
Ileocecal Area	6	6
Overall Image	3	Tomosynthesis × 1
Examination Time	20min	20min

**Fig. 14** Workflow for Intestinal Infusion Before and After Introduction of Tomosynthesis



**Fig. 15** Clinical Images



**Fig. 16** Clinical Images

In terms of the future prospects for tomosynthesis, we believe action needs to be taken to actively make physicians aware of the technique. Tomosynthesis has the disadvantage relative to CT of only creating tomographic images in the scanning direction, and cannot create a three-dimensional reconstruction as with MPR, but considering the exposure time and exposure doses involved there is considerable potential for its application not only in the field of orthopedics where it sees the greater part of use present, but also in gastrointestinal contrast radiography as one example. The slow mode normally results in 74 views, but at this hospital and with a normal reconstruction pitch of 1 mm this number becomes around 100 images. The monitor display is an essential piece of equipment for observation when considering this amount of images, and we see the ancillary equipment used to read and interpret these images becoming more important with time.

## 7. Conclusion

Tomosynthesis is extremely effective for colon X-ray examination of areas with complex topographies and lesions. Furthermore, imaging of the entire colon is an effective way of making sure smaller lesions are not missed.

By using appropriate X-ray parameters, the exposure dose to the patient can also be reduced to amounts below plain radiography. We intend to perform further studies of tomosynthesis and actively pursue its adoption in the clinical environment.

This article is excerpted and rewritten based on presentations given at the 2011 Kanto & Koshinetsu Conference of Radiological Technologists, and the 2012 Conference of the Japan Association of Radiological Technologists.

## References

- 1) 2004 White Paper on Cancer and Statistics
- 2) Ryohei Fukui, Experiences Using the SONIALVISION safire Series – Investigation into Tomosynthesis of the Temporomandibular Joint, MEDICAL NOW 2011 No.70, P4–8
- 3) Manabu Takehara, Experiences Using the SONIALVISION safire Series, MEDICAL NOW 2011 No.71, P9–13
- 4) Masahiro Iwama et al, Use of Tomosynthesis at the Aizawa Hospital, MEDICAL NOW 2011 No.72, P7–11