

Experiences with Cochlear Implant examination Using Tomosynthesis

Department of Radiology, Shinshu University Hospital

Manabu Takei

Introduction

Cochlear implants comprise instruments positioned inside and outside the body. The external microphone receives external sounds, which are converted to electrical signals by a speech processor and then transmitted into the body by an antenna. The signals introduced into the body are transferred as electrical signals by the intracochlear electrodes into the auditory nerve to be perceived as sound. The type and intensity of the sound differ according to the combination of stimulated electrodes. At this hospital, we use cochlear implants with 12 or 24 electrodes.

Utility of Tomosynthesis

CT and MRI are currently the mainstream imaging methods for the head and neck region. However, electrodes and other metal components can cause artifacts that destroy information. Tomosynthesis, however, achieves high spatial resolution with few metal artifacts and can acquire multiple tomographic images from a single acquisition, making it ideal for detailed examinations of cochlear implants. Positioning under fluoroscopy can be performed prior to radiography to avoid overlapping of electrodes and to enhance reproducibility.

Aim

At this hospital, inner ear tomography by tomosynthesis has become routine for post-operative evaluations after cochlear implant surgery. In addition to providing clinical images, we report on our investigation of patient positioning and the effects of the swing angle and image reconstruction filters to acquire images with maximum utility for diagnosis.

Images Deemed Useful

Section images perpendicular to the modiolus (parallel to the turn of the lamina basilaris cochlea) that show the electrodes inserted into the cochlear in a single sectional image. Images with minimal artifacts that maintain the contrast between the electrode and cochlear wall are deemed to be useful images.

Method

- 1) Investigating the Tomography Swing Angle
A glass dosimeter was attached to the orbital region of a head phantom. The exposure dose was measured at the lens position at swing angles of 8°, 30°, and 40°. Next, a 10 cm acrylic phantom was used with a one-yen coin positioned at a height of 5 cm and the SN ratio was determined using the following equation:
$$\text{SNR} = \text{Mean Signal} / \text{SD BG}$$
- 2) Investigating Image Reconstruction Filters
The SN ratios for an SNR measurement phantom containing embedded CaCO₃ of different densities (manufactured by Kyoto Kagaku Co., Ltd.) were calculated and compared for image reconstructions using shift-and-add, filtered back projection (FBP), and FBP + CV filters (DC4, 6, 8, 10). Clinical images obtained while changing the reconstruction filters (as above) were evaluated by an ear, nose and throat specialist.

Results

- 1) The larger the swing angle, the lower the exposure dose at the lens (organ at risk) (**Fig. 1**). This is believed to occur because the distance from the focal point to the lens increases as the swing angle becomes larger. When measuring the SN ratio with an acrylic phantom, the pixel values vary little with the swing angle, but the SD tends to decrease as the swing angle increases. Therefore, the SN ratio increases as the swing angle increases (**Fig. 2**). Consequently, the swing angle was set to 40°.
- 2) The investigations into image reconstruction filters reveal that filtered back projection (FBP) achieved the highest SN ratio, and the SN ratio dropped off as the direct current (DC) component increased (**Fig. 3**). Inputting DC components during clinical image evaluation reduces undershooting but tends to lose the contrast of the electrode and cochlear wall. Consequently, we selected filtered back projection (FBP) as the image reconstruction filter (**Fig. 4**).

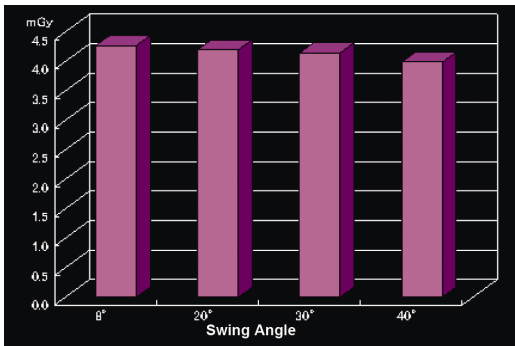


Fig. 1

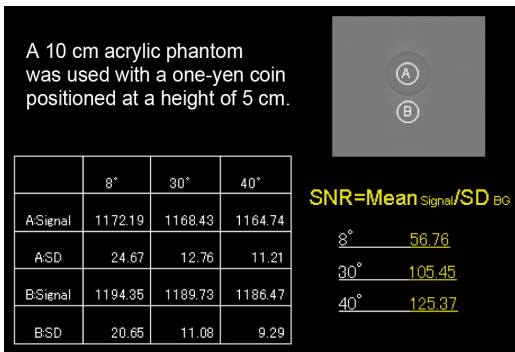


Fig. 2

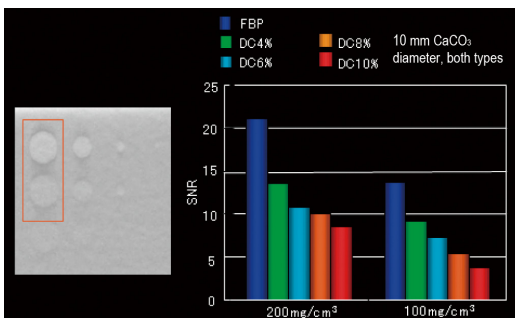


Fig. 3

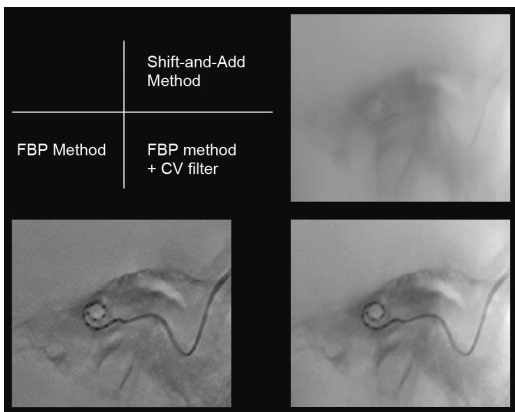


Fig. 4

Radiography Conditions and Clinical Images

The radiography conditions are shown below. The patient positioning is based on the Stenvers method, due to the wider view of the base of the lamina basilaris cochlea. As the examination was performed immediately after surgery, radiography was performed using the reverse Stenvers method in the supine position.

System used: SONIALVISION safire
 Positioning: Reverse Stenvers method
 80 kV, 1.8 mAs, 7.1 ms
 SID: 110 cm 6 inch

Tomography swing angle: 40°
 Tomography speed: Fast
 Frames: 67 frames
 Image reconstruction method: FBP
 Image reconstruction pitch: 1 mm

Case 1: 68-year-old male

A cochlear implant was surgically implanted on the right side due to advanced bilateral sensorineural hearing loss. Fig. 5 shows a tomosynthesis image taken on the day after surgery. All 12 electrodes are visible in a single sectional image and the contrast of the cochlear wall is maintained. The position was confirmed at the center of the cochlear nerve and distances could be measured.

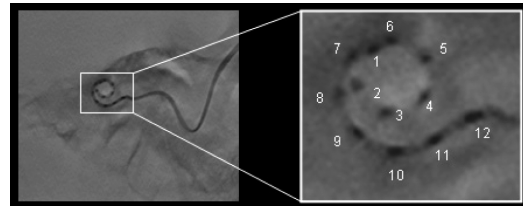


Fig. 5

Case 2: 32-year-old male

A cochlear implant was surgically implanted on the right side due to advanced bilateral sensorineural hearing loss. Fig. 6 shows an image of the 24 electrodes. All 24 electrodes are visible in a single sectional image, but the distances between the electrodes are less distinct than for 12 electrodes. This results from the effects of adjacent electrodes in the tomographic direction due to the short distances between the electrodes.




Fig. 6

Discussion

Tomosynthesis suffers less from metal artifacts, achieves higher spatial resolution, and acquires images at a lower exposure dose than computed tomography (CT). For inner ear radiography, viewing all electrodes in a single sectional image using filtered back-projection (FBP) is relatively simple due to the increased slice thickness. However, careful consideration of the cochlear angle and tomographic direction is required to separate each electrode. As the contrast is maintained between the electrodes and cochlear wall, it is possible to measure distances from the modiolus to the electrodes and to cochlear wall. Consequentially, tomosynthesis has utility for the post-operative evaluation of cochlear implants.