

Use of Tomosynthesis Radiography for Total Hip Arthroplasty (THA) at Iida Hospital

Department of Radiology, Iida Hospital
Shota Horitake



Mr. Shota Horitake

1. Introduction

Iida Hospital (Fig. 1) was established in 1903 in southern Nagano Prefecture, located in what is now Iida City. Iida Hospital currently has 452 beds, including 212 beds for general patients and 240 beds for psychiatric patients, provides medical services in all medical fields, and has a dedicated outpatient medical service. The principal of our hospital is *Jin no Kokoro*, which translates as "Benevolent Heart." As a core hospital of the region, we endeavor to provide medical care that recognizes our founding ideals and also is deeply rooted in the local community. With an eye to the future of medical care, we also strive to provide familiar but advanced medical services that are trusted by the local community.



Fig. 1

2. Present Situation

In 2013, our hospital performed 505 orthopedic surgical procedures, of which total knee arthroplasty (TKA) and total hip arthroplasty (THA) accounted for 320, or around two-thirds of those procedures (Fig. 2). These procedures were performed using tomosynthesis radiography for follow-up observations. The number of times tomosynthesis radiography has been used since we installed a SONIALVISION safire series (Fig. 3), a period of about 1 year and 4 months up to June 2014, is shown in Fig. 4. In this period, we used tomosynthesis radiography 553 times. This number accounts for about one quarter of all fluoroscopy examinations during that

time period (Fig. 5). Because most of these 553 examinations were related to THA (429 examinations, 78 %) and TKA (97 examinations, 18 %), we also find more and more of our examinations are performed using T-smart (Tomosynthesis-Shimadzu metal artifact reduction technology) for image reconstruction due to its ability to further reduce the appearance of metal artifacts (Fig. 6).

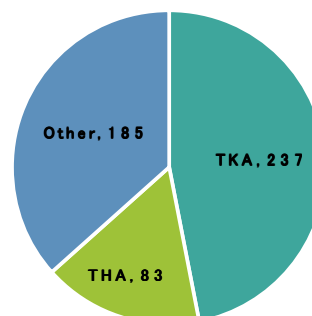


Fig. 2 Number of Orthopedic Surgical Procedures (2013)



Fig. 3

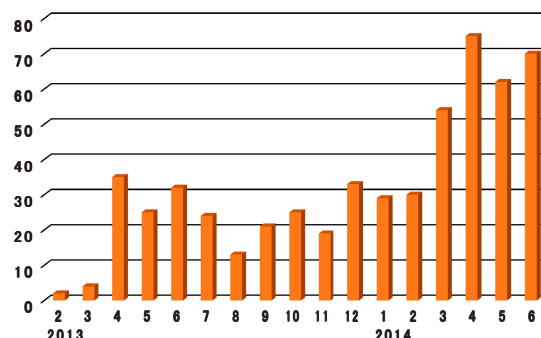


Fig. 4 Tomosynthesis Radiography Usage by Month

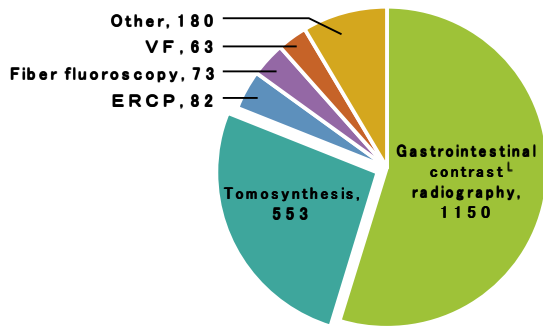


Fig. 5 Breakdown of All Fluoroscopy Examinations

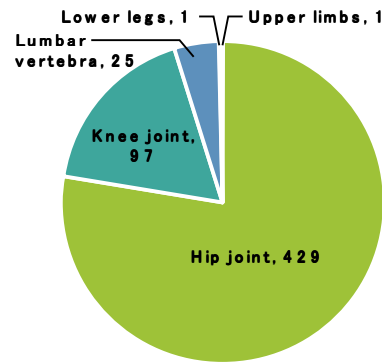


Fig. 6 Breakdown of Tomosynthesis Radiography Examinations

3. Tomosynthesis Radiography of the Hip Joint

Here, we report on the most common use of tomosynthesis radiography at our hospital, that of hip joint imaging. On a busy day a single radiation technologist performs tomosynthesis radiography of 5 to 6 patients in the morning, and even then 2 to 3 patients are normally waiting to be examined. The image processing that occurs after radiography needs to be quick as patients will consult with the doctor following the examination. At our hospital, we take the filtered back projection (FBP) image that is created automatically after radiography, choose the area of the image to be reconstructed, and use T-smart processing for reconstruction of that area. T-smart image reconstruction takes about 4 minutes for one hip joint and 10 minutes for both, so it must be performed immediately after the radiology examination ends. The procedure at our hospital is for a patient to be called in, radiology to be performed, and T-smart processing to commence, at which point the processed image from the previous patient is sent via PACS (Fig. 7).

Although our hospital has no set radiography protocol, radiography is performed at patient examination at discharge from hospital and at 1 month after discharge to confirm early phase bone growth, after

which the radiography schedule will differ for each patient.

Radiography is normally performed in a loaded position (table tilt angle of 75°). If the patient's abdomen is large due to obesity or for other reasons, we immobilize the patient in place with a wide belt fastened across the patient's lower abdomen so that body thickness does not affect the image (Fig. 8). For elderly patients or other patients with a curved back, we also prefer to immobilize the upper body with a belt, as the upper body can become unstable and be a cause of concern for the patient.

Radiography conditions and image reconstruction parameters are shown in Fig. 9. The ideal situation is for the patient to be positioned correctly in all three dimensions. Reproducing a given position over the course of follow-up observations is difficult, so we check positioning using fluoroscopy. For example, when a femur stem that contains holes (e.g., SL-PLUS MIA) is present, when positioned correctly, the holes will appear as perfect circles. Accordingly, we take great care to achieve a good position (Fig. 10). Differences in position will affect greatly the apparent stem width, hole shapes, and visualization of edges. Inaccurate positioning can result in stem edges appearing indistinct (Fig. 11).

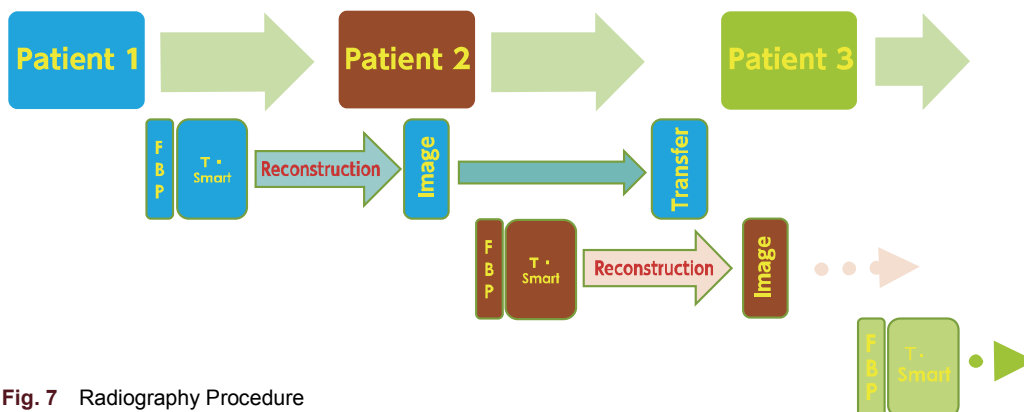


Fig. 7 Radiography Procedure

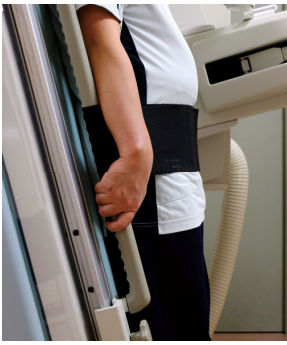

Fig. 8

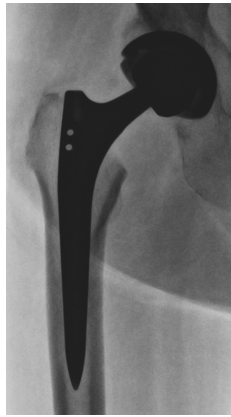

Fig. 10

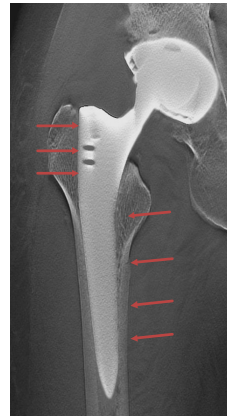
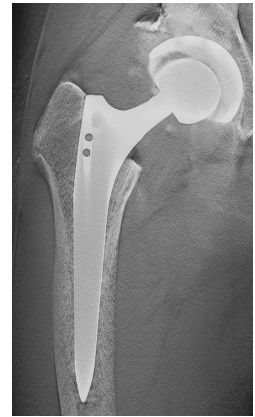


Fig. 11



Standing (75°)	Reconstruction mode IR
Tube voltage 85 kV	Metal L or LL
Tube current 400 mA	Pitch 2mm
Plane angle 40°	No. of iteration 4

Fig. 9

4. Case Study Photographs

We performed radiography of 7 different THA stems: SL-PLUS MIA, VECTOR-Titan, SUMMI stem, S-ROM-A, TRI-Lock stem, Accolade stem,

and Super Secur-fit Plus. These 7 stems come in various cross-sectional shapes such as quadrilateral, polygonal, and concave, and may also have slits (Fig. 12).

Clinical examples are shown below.




Fig. 12 Stems

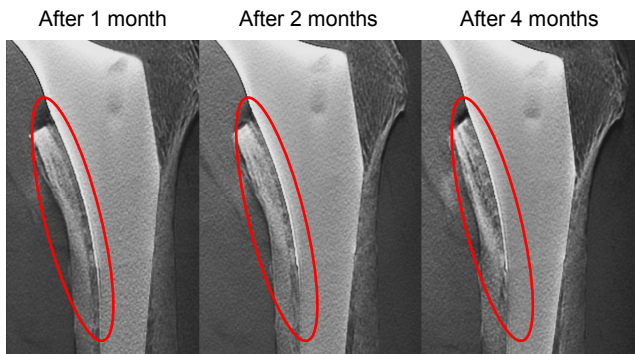

Fig. 13 Accolade Stem
With the Accolade stem, bone is encouraged to grow onto the stem. Changes on the inner surface of the bone appear at 2 months after surgery, and at 4 months after surgery the bone can be observed to have grown onto the stem.

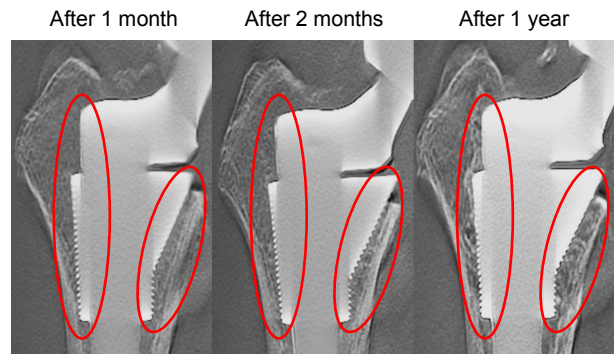


Fig. 14 S-ROM-A
A small amount of bone growth can be observed on the inner surface of the bone at 2 months after surgery, and after 1 year a substantial amount of growth can be seen. Changes on the outside of the bone can also be observed.

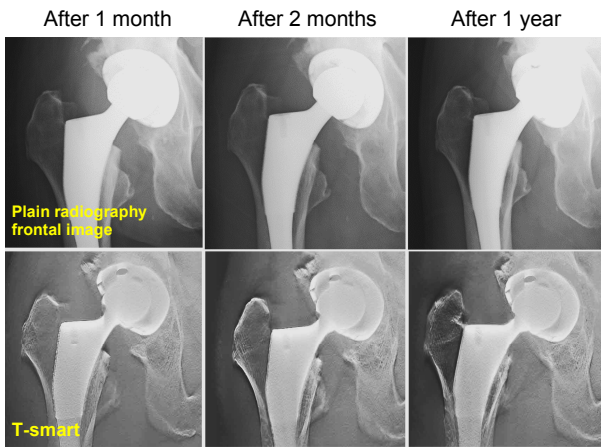
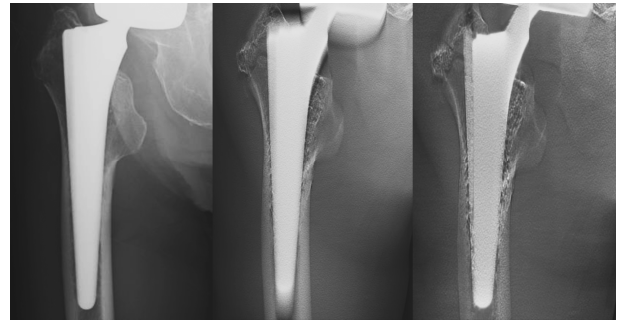


Fig. 15 TRI-Lock Stem
Plain radiography frontal images and T-smart images of a patient with stress shielding. Near to no change can be seen in the plain radiography frontal image at 2 months after surgery, while in the T-smart image changes in the bone can be seen to have appeared. At 1 year after surgery changes in the bone can be seen in the plain radiography frontal image, but in the T-smart image these same changes can be observed more clearly.



Plain radiography frontal image FBP (DC2) T-smart

Fig. 16 VECTOR-Titan
Comparison of a plain radiography frontal image and tomosynthesis images of a patient with a bone fracture caused by a fall. The fracture line in the greater trochanter is difficult to make out on the plain radiography frontal image, but can be confirmed with FBP. Nevertheless, the T-smart image is clearer still in terms of reduced artifacts and visualizing fine detail in the trabecular bone.

5. Case Study (Strategies for Reducing Artifacts)

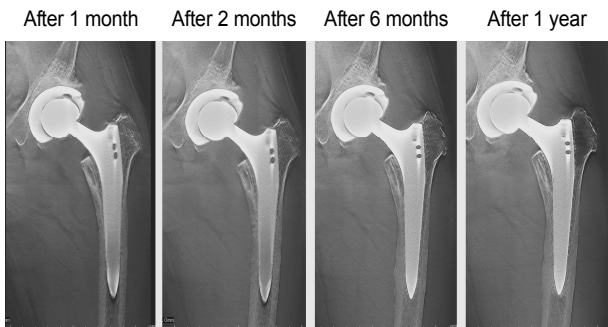

Fig. 17 SL-PLUS MIA
A patient has undergone 4 follow-up radiography examinations by 1 year after surgery. All the images use the Metal L filter and the same reconstruction parameters. Undershoot artifacts are present at the lower end of the stem in images at 1 and 2 months after surgery, possibly due to incorrect positioning. When performing follow-up observations such as these, positional accuracy is considered a primary condition for the prevention of artifacts.

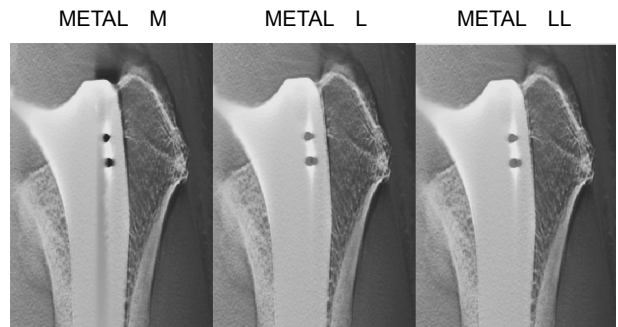


Fig. 18 SL-PLUS MIA
AN example of artifacts occurring on the outside of the stem. Using the Metal M filter, there are artifacts between the bone and stem that seem to show the stem is loose within the bone. However, changing to a Metal L or Metal LL filter reduces these artifacts. As such, we can routinely reduce the appearance of artifacts by trying different metal filters for reconstruction, when artifacts occur.

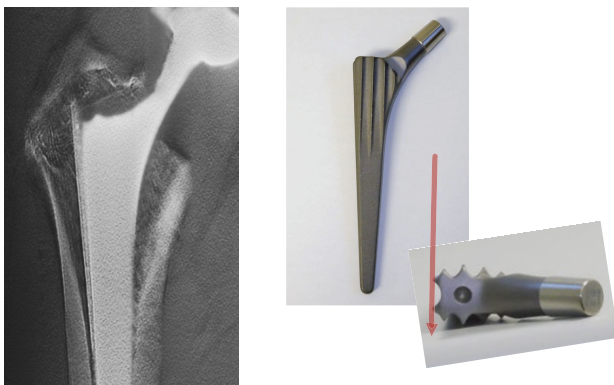


Fig. 19 VECTOR-Titan
With this complex polygon-shaped stem (VECTOR-Titan), strong artifacts can appear between the center of the stem and the distant cross section of the stem. Most of these artifacts originate from poor positioning, and so we prefer to use fluoroscopy images to check the angle of the stem so that the outside slits overlap in the direction of incident X-rays.

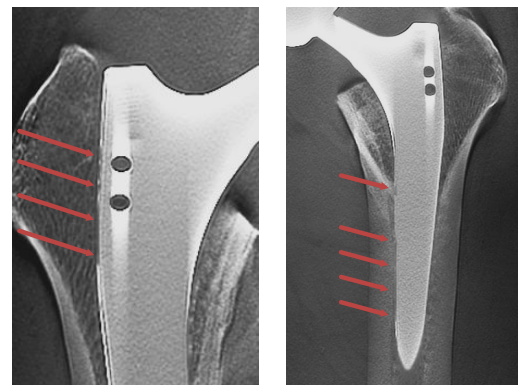


Fig. 20 Artifacts that occur with T-smart tend to be seen on the left side of the image, regardless of whether the stem is inserted towards the left or right side.

6. Future Topics

New metal filters THA L and LL, have been added to T-smart that can be used alongside the existing Metal M, L, and LL filters. The new filters come with no substantial difference in processing time, while also reducing metal artifacts and improving precision for image visualization. They provide in an overall improvement in visualization capabilities, and in particular an improvement to the artifacts that tend to occur on the left side of stems. However, as mentioned above, while it is desirable to employ the appropriate metal filter to obtain accurate visualization of a given metal, since our SONIALVISION safire system was only recently installed (it is October 2014 as of writing), and so we must leave the validation of stem/filter combinations to another article.

7. Summary

Image uniformity is required when performing follow-up observations of THA patients using tomosynthesis radiography. When performing radiography, it is important to pay attention to the following.

- Positioning should be correct in all three dimensions.
- Fasten a belt around the lower abdomen of the patient to contain the effects of body thickness.
- Radiography conditions should be constant, including the angle of table tilt, radiography size, and collimation.
- Reconstruction and image display parameters should also be constant.

Tomosynthesis radiography allows us to elucidate changes in the bone just a few months following surgery, and to assess the condition of bone fixation to the stem earlier than before. T-smart also reduces metal artifacts and gives a clearer visualization compared to FPB. We also believe the newly added metal filters will improve the visualization capabilities of T-smart.

Finally, while our hospital currently uses tomosynthesis radiography only in the field of orthopedics, we wish to pursue the possibility of widening its use into other medical fields.