

# Usefulness of Tomosynthesis in ERCP Procedures and Experience Using T-smart



Mr. Hideki Yamaguchi

Department of Radiology, Nippon Koukan Hospital<sup>1</sup>

Department of Internal Medicine, Nippon Koukan Hospital<sup>2</sup>

Hideki Yamaguchi<sup>1</sup>, Yoshitami Murayama<sup>1</sup>, Seiji Otsuka<sup>2</sup>, Kenji Ogawa<sup>1</sup>

## 1. Introduction

Nippon Koukan Hospital was founded in 1937 as the first general hospital in Kawasaki City, Kanagawa Prefecture (Fig. 1). Koukan Clinic (Fig. 2) was established alongside the main hospital October 2003, which provides community-based health care as a core hospital. In August 2003, the hospital established a gastroenterological and hepatic disease center, the first facility in Kawasaki Ward to be accredited by the Japan Society of Hepatology, and to this day continues its focus on gastroenterological endoscopy-based diagnosis and treatment of disease. The Department of Radiology uses Shimadzu's SONIALVISION safire and SONIALVISION G4 systems to perform tomosynthesis in endoscopic retrograde cholangiopancreatography (ERCP) procedures. In this article, we describe the recently acquired T-smart, an image reconstruction function for tomosynthesis, which we found to be effective for ERCP procedures.

## 2. Aims of Using Tomosynthesis in ERCP Procedures

- To render common bile duct stones
- To check for residual material after stone extraction

Tomosynthesis was introduced to ERCP procedures

with the above aims. The aim of using tomosynthesis is to render stones, because knowing the size of bile duct stones allows the doctor to choose between endoscopic papillary balloon dilatation (EPBD) or endoscopic sphincterotomy (EST) procedures, and to keep incisions to the necessary minimum during EST. In addition, the aim of using tomosynthesis to check for residual matter after stone extraction is to reduce the risk of pancreatitis and cholangitis caused by repeat treatment, and so shorten examination times and reduce patient burden.

## 3. Background to Using Tomosynthesis in ERCP Procedures

Our hospital started using tomosynthesis since it obtained a SONIALVISION safire system in September 2005. Since tomosynthesis was one of the features included in the R/F table, our hospital investigated whether tomosynthesis could be used effectively in fluoroscopic examinations, and as a result used tomosynthesis in ERCP procedures. At first, a scanning time of 15 seconds caused scanning to be affected by patients unable to hold their breath and vascular movement caused by the heart beat, and use of tomosynthesis decreased since it did not bring the expected improvements in diagnostic performance. However, system improvements reduced scanning



Fig. 1



Fig.2

times (fast mode: 2.5 seconds, slow mode: 5 seconds) sufficient to allow its use in the abdominal region, and the number of examinations performed with tomosynthesis subsequently increased. At present, our SONIALVISION G4 (Fig. 3) system is also capable of tomosynthesis.

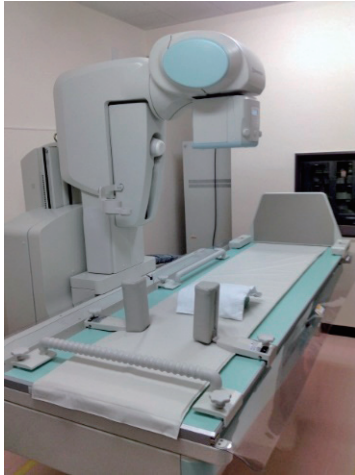

Fig.3 SONIALVISION G4

## 4. Detection of Common Bile Duct Stones by Tomosynthesis

A report was presented at ECR 2015 on the performance of tomosynthesis in rendering stones during ERCP procedures. The report compared the rendering performance of tomosynthesis against contrast enhanced SPOT radiography (hereinafter, "SPOT radiography") during ERC procedures in 102 patients performed at our hospital. The report by Suyama et al.<sup>(1)</sup> evaluated ROC analysis, sensitivity, specificity, accuracy, positive predictive value (PPV), and negative predictive value (NPV), and showed that tomosynthesis provided higher sensitivity and NPV than SPOT radiography for rendering common bile duct stones, and also avoided unnecessary EST.

## 5. Scanning Conditions and Reconstruction Parameters

Table 1 Scanning Conditions

|  |                           |
|--|---------------------------|
| Tube Voltage                                   | 90kV                      |
| Tube Current                                   | 160mA                     |
| Scanning Time                                  | 16msec                    |
| Tomographic Angle                              | 40 degrees                |
| Scanning Mode                                  | Fast (2.5sec)*1           |
| Subject height from tabletop (During scanning) | 10 mm (Prone position) *2 |
| Field-of-View Size                             | 12inch *3                 |

A tube voltage of 90 kV is used for tomosynthesis (Table 1). According to "Efficacy of Tomosynthesis in Endoscopic Retrograde Cholangiopancreatography," a presentation delivered at the 63rd Annual Meeting of the Japanese Society of Radiological Technology, good visualization is obtained at this tube voltage.

- \*1: Minimum scanning times are used due to the need for respiratory standstill. One of the reasons for using the fast scanning mode (2.5 seconds) is that respiratory standstill is difficult to achieve in many patients due to sedation. Also, ripple artifacts caused by endoscope fiber optics are reduced by using fewer scans, which contributes to improved visualization of the common bile duct.
- \*2: When ERCP procedures are performed with the patient in a prone position, subject height is set as low as possible to distinguish between the common bile duct and endoscope fiber optics, so the X-ray angle of incidence is set to maximum at the subject height (common bile duct thickness).
- \*3: The subject height is set as low as possible and the angle of X-ray incidence is set to a maximum at the subject height. And when performing tomosynthesis of the region from the Vater's papilla to the intrahepatic bile duct, the region of interest can be out of the field of view when scanning is performed at 40 degrees. Because of this, image degradation can be prevented during reconstruction by using a field-of-view for

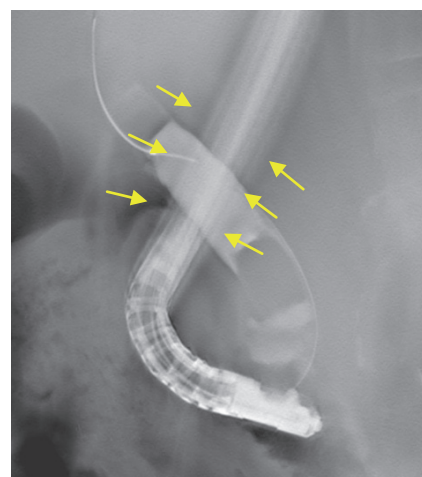


Fig. 4 Ripple Artifact (76 images acquired)

Table 2 Reconstruction Parameters

|                                 | FBP        | T-smart (IR)                        |
|---------------------------------|------------|-------------------------------------|
| Reconstruction Parameter        | Metal+     | Metal S                             |
| Reconstruction pitch            | 5mm        | 2mm                                 |
| Reconstruction Time (12 inches) | 12 seconds | 1 minute 36 seconds (IR 3 times) *4 |

\*4: Reference values: 3 times for IR, shutter used, mean of 3 times for FBP and IR

tomosynthesis that is one size larger than that used for fluoroscopy.

At our hospital, Metal+ is used for FBP reconstruction and Metal S for IR (T-smart) reconstruction (**Table 2**). Using Metal S for IR reconstruction allows separation between endoscope fiber optics and common bile duct, except when the fiber optics is moving due to incomplete respiratory standstill or the gap between the fiber optics and common bile duct is extremely narrow.

\*4: Because tomosynthesis is used in ERCP procedures to confirm the number and size of stones, and check for residual stones, tomographic images must be examined instantaneously. At our hospital, images reconstructed by FBP is used initially to provide images for clinical use due to the shorter reconstruction time, after which image reconstruction is performed again by IR (T-smart). Using FBP, the reconstruction time varies depending on the number of reconstructed images, while reconstruction times are not so dependent on the number of reconstructed images when using IR. Reconstruction times can also be shortened with shutter usage and by performing reconstruction calculations for only the necessary region.

### 6. Cases Indicated for Tomosynthesis at Our Hospital

Cases indicated for tomosynthesis at our hospital include:

- When stones are not found with contrast enhancement (cases where stones have been found by another imaging modality, or cases where the presence of stones is not clear but suspected strongly with contrast enhancement)
- Visual contact with stones is lost due to wire or other device manipulation
- To ascertain the number and size of multiple stones
- When there is a need to differentiate between the cystic duct and common bile duct
- When there is artifacts interference caused by overlapping endoscopy fiber optics, gastrointestinal gas, or leaked contrast media

Tomosynthesis is not used at our hospital in cases of one-off development of stones, or when the presence of stones is obvious.

In addition, we have found stones cannot be rendered by tomosynthesis in circumstances that include:

- When respiratory standstill is not possible
- Cases not compatible with contrast media use (Rendering is sometimes not possible when contrast

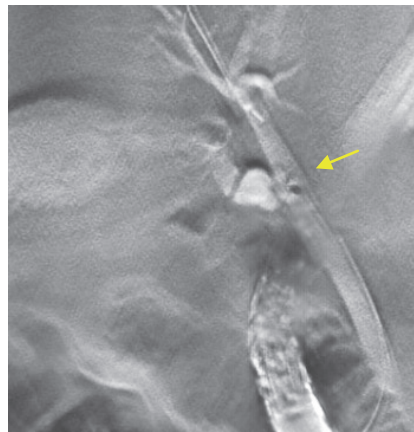
media is not inserted to a certain level.)

- Spatial relationship between common bile duct and fiber optics (unable to distinguish between common bile duct and fiber optics when fiber optics are parallel to the direction of X-ray tube movement)

### 7. Examples of Tomosynthesis in Use

#### Case 1: Common bile duct stone (junction with cystic duct)

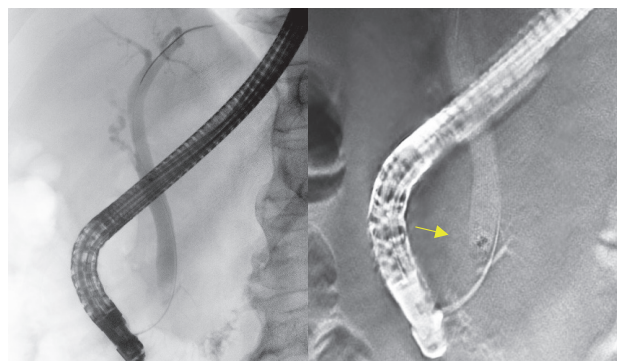
Admitted for obstructive jaundice. Common bile duct stone suspected, but not found on CT and ultrasound, so ERCP performed to confirm (**Fig. 5**). Stone found at junction with cystic duct on tomosynthesis, and stone extraction surgery performed.



**Fig. 5** Arrow: Stone rendered clearly at junction between cystic duct and common bile duct

#### Case 2: Common bile duct stone

Admitted for acute pancreatitis. CT revealed findings of acute pancreatitis but no stone in the common bile duct. Pancreatic stone suspected and so ERCP performed. Confirming stone presence in contrast enhanced images hampered by overlapping gastrointestinal gas, but stone rendered clearly by tomosynthesis (**Fig. 6**). Stone found in common bile duct and stone extraction surgery performed.



**Fig. 6** Arrow: Presence of stone not clear on SPOT radiography (left) due to overlapping gastrointestinal gas. Stone in common bile duct rendered clearly by tomosynthesis (right)

## 8. Example of Tomosynthesis in Use (T-smart)

Fiber optics (shadow) disappear when using T-smart (Fig. 7), which clearly renders a common bile duct stone that overlaps with fiber optics in Fig. 8 (←).

## 9. Exposure Dose

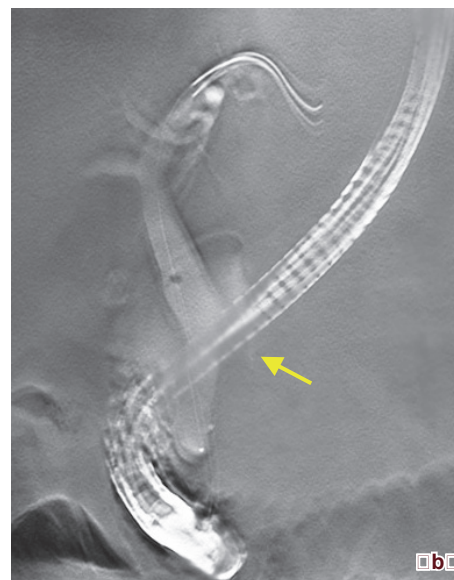
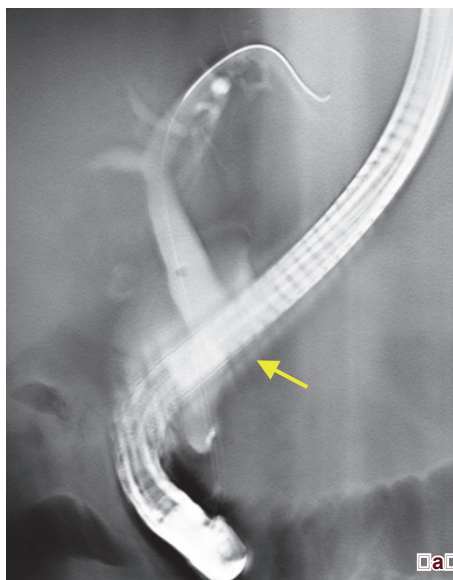
Exposure doses calculated by PCXMC Monte Carlo simulation using the conditions shown in Table 3 were 0.089 mSv for SPOT radiography and 0.793 mSv for tomosynthesis. Although the exposure dose for tomosynthesis is 8.9 times higher than SPOT radiography, because the need for radiographies from multiple directions to confirm stone presence is eliminated by tomosynthesis, and

the treatment and examination times can probably be shortened due to the superior visibility provided by tomosynthesis, tomosynthesis is adequate for use in ERCP procedures. Exposure doses can probably be reduced further using IR (T-smart), a recently introduced technology, and our hospital intends to review scanning conditions in the future to further reduce exposure doses.

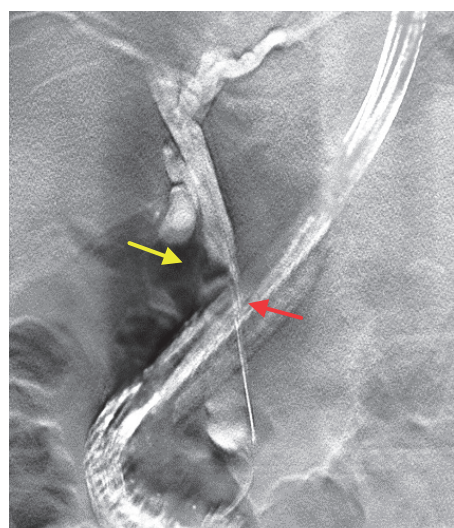
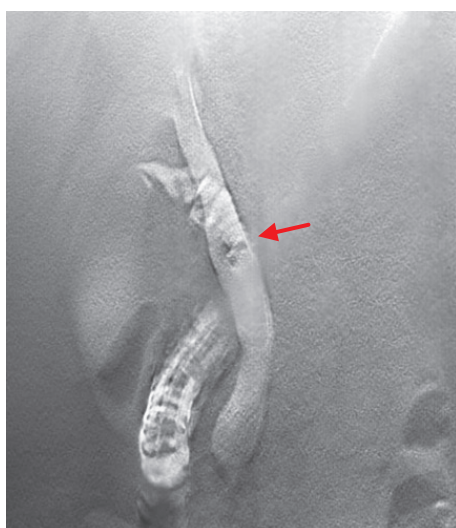**Table 3** Comparison of Tomosynthesis and SPOT Radiography Exposure Dose (mSv)

|                   | Tomosynthesis             | SPOT Radiography |
|-------------------|---------------------------|------------------|
| Tube Voltage      | 90 kV                     | 82 kV            |
| Tube Current      | 2.5 mAs                   | 25.6 mAs         |
| Scanning Mode     | Fast (36 images acquired) | Single Shot      |
| Effective Dose *5 | 0.793 mSv                 | 0.089 mSv        |

\*5: Calculated using PCXMC



**Fig. 7** Comparison of FBP and IR (T-smart: Metal S) (same patient)  
(a) FBP (Metal+) (b) T-smart (Metal S)



T-smart (Metal S)

T-smart (Metal S)

**Fig. 8**

## 10. Results of Using Tomosynthesis

On performing a retrospective review of all 165 cases that underwent endoscopic common bile duct stone extraction surgery at our hospital during the 5-year period between January 2011 and December 2015, we found repeat stone extraction surgery was performed in 18 cases (11 %). Among the 78 of these cases where tomosynthesis was performed, repeat stone extraction surgery was performed in 4 cases (5 %), while among the 87 of these cases where tomosynthesis was not performed, repeat stone extraction surgery was performed in 14 cases (16 %). Looking at the 4 cases where tomosynthesis was performed and also underwent repeat stone extraction surgery, in 2 cases tomosynthesis performed before surgery revealed multiple stones that could not be extracted completely due to the large number present, in 1 case stones were not rendered by tomosynthesis due to incomplete respiratory standstill, and in 1 case stones were not rendered by tomosynthesis due to air in the common bile duct caused by treatment performed after stone extraction surgery. Cases where tomosynthesis was not performed includes patients in whom respiratory standstill was not successful and cases where the ERCP procedure itself was a challenge due to poor physical condition. Although no general conclusion can be reached because of these mitigating factors, the results indicate that tomosynthesis use in ERCP procedures is useful for the treatment of common bile duct stones.

## 11. Summary

If performing tomosynthesis during ERCP procedures reduces the number of stone extraction surgeries,

the risk of complications such as pancreatitis and cholangitis arising after treatment can be reduced. Also, the biggest advantage of using tomosynthesis in ERCP procedures is being able to confirm the size and number of stones, and thereby minimize use of EST. Tomosynthesis also makes it easy to determine treatment efficacy by confirming the absence of stones after stone extraction surgery, which can reduce patient burden by shortening the duration of treatment. During an ERCP procedure, there are significant constraints on our ability to render and confirm the presence of stones, including the difficulties involved in changing the position of the patient. Tomosynthesis is effective when gastrointestinal gas, leaked contrast media, or the cystic duct overlaps the target area. While not covered in in this article, tomosynthesis can also be used to create oblique tomographic images, and these images are one of the reasons the common bile duct and cystic duct can be separated in reconstructed images without requiring changes in body position. As shown in section 6, because some cases are not suited to tomosynthesis and tomosynthesis does not necessarily render all stones, for tomosynthesis to contribute to the smooth implementation of treatment and alleviation of patient burden, it should be used appropriately and in circumstances that require it.

Results suggested the number of cases that undergo repeat stone extraction surgery can be reduced by using tomosynthesis in ERCP procedures, and also confirmed the usefulness of tomosynthesis.

### Reference

- 1) Y.Suyama, Y.Yamada, G.Someya, S.Otsuka, H.Yamaguchi, Y.Murayama, M.Jinzaki, K.Ogawa.: Tomosynthesis for the detection of choledocholithiasis: diagnostic performance compared with radiography for Endoscopic retrograde cholangiography. European Society of Radiology, ECR2015, C-1448, 1-12, 2015