

Evaluation of Early biological bone ingrowth for Cementless stem using tomosynthesis.

Department of Orthopaedic Surgery, Yufuin Hospital¹ and Department of Orthopaedic Surgery, Oita University²
Koichi Hara¹ (currently at Hara Orthopaedic Surgery clinic), Shuta Shin¹, and Nobuhiro Kaku²

1. Objectives

Radiography (Xp) images are often inadequate for an evaluation of early biological fixation for cementless stems of total hip arthroplasty (THA) and bipolar hip arthroplasty (BHA). We investigated the validity of using tomosynthesis (TS) to evaluate early biological fixation between the femur and cementless stem.

2. Subjects and Methods

Subjects included 37 joints among 33 patients who underwent a primary THA and/or BHA with a cementless stem between October 2012 and July 2015.

Men: 7 joints **Women:** 30 joints **Age:** 74 years (41-96 years)
Height: 151.5 cm (131.5-171 cm)
Weight: 51.2 kg (28.7-81.7 kg) **BMI:** 22.1 (14.1-35.4)
Disease: Osteoarthritis (OA) of the hip 18 joints
Rheumatoid arthritis 1 joint
Femoral neck fracture 15 joints
Rapidly destructive osteoarthritis of the hip 1 joint
Osteonecrosis of the femoral head 2 joints

Shape of the femoral canal: (Noble et al.)
Champagne flute: 2 joints; Normal canal: 24 joints; Stovepipe: 11 joints
Stem alignment: 3-degree or greater from femoral axis were defined as varus or valgus.
Intermediate position (intermediate group): 33 joints; Varus position (varus group): 4 joints; Valgus position (valgus group): 0 joints

Frontal view TS and Xp images were obtained at 2 weeks, 12 weeks, and 6 months after surgery. Findings of evaluation item number 1 to 9 shown below were evaluated in each Gruen zone, and the emergence rates of finding were compared.

Evaluation items:
1 (Reactive line), 2 (Radiolucent line), 3 (Spot welds)
4 (Cancellous condensation: bone ingrowth)
5 (Cortical hypertrophy), 6 (Stress shielding)
7 (Subsidence: 2 mm or more), 8 (Pedestal formation)
9 (Occult fracture)

- Comparison based on shape of the femoral canal, and stem alignment
- Comparison of findings of biological fixation (cancellous condensation/spot welds) based on stem shape/surface finish.
Stem shape: Fit and fill vs Tapered wedge
SUMMIT 7 joints vs ANTHOLOGY + Taperloc Micro. 9 joints
Surface finish: 3D porous vs Porous vs Porous + HA
Trabecular 6 joints vs SUMMIT 7 joints vs 910 PerFix 11 joints
- Statistical significance test: t-test, Fisher test (* p<0.05)

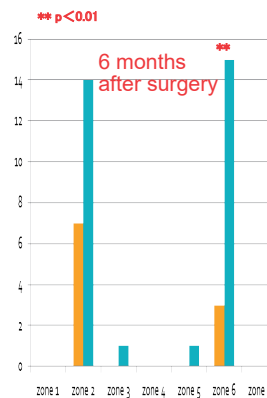
Table 1 Stem Model Name and Features

Stem Model Name	Number of Joints	Shape	Surface Finish
910 PerFix HA Collarless	11 joints	Fit & Fill	Porus + HA
ELANCE AHFIX	1 joint	Zweymuller	Gridblast
SUMMIT Porocoat	7 joints	Fit & Fill	Porus
VerSys HA/TCP Fiber Metal	2 joints	Fit & Fill	Porus + HA
Trabecular Metal	6 joints	Fit & Fill	3D Porus
Alloclassic Zweymuller SL	1 joint	Zweymuller	Gridblast
ANTHOLOGY	2 joints	Taper Wedge	Porus
Taperloc Complete Microplasty	7 joints	Taper Wedge	Porus

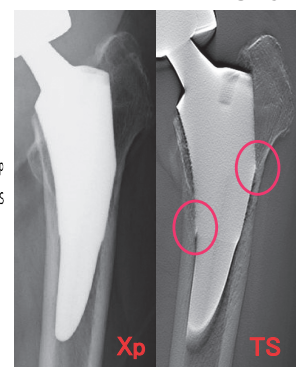
3. Results

The emergence rates of evaluation item 3 (spot welds), 4 (cancellous condensation), and 6 (stress shielding) were significantly higher in TS images compared to Xp images.

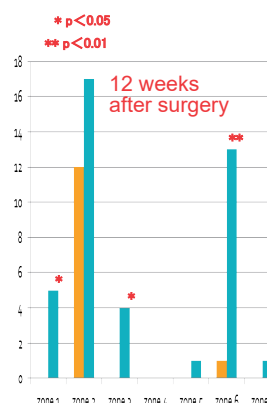
Evaluation item 3 (Spot Welds)



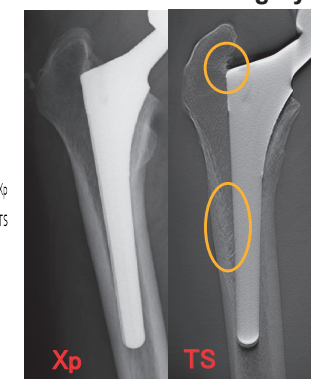
6 Months After Surgery



Evaluation item 4 (Cancellous Condensation)



12 Weeks After Surgery



Evaluation item 6 (Stress Shielding)

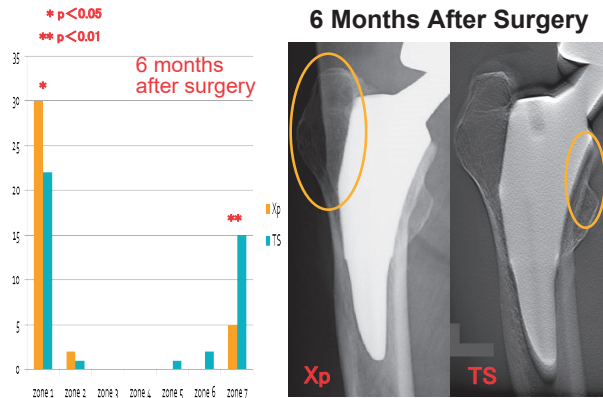


Table 2 Summary of Findings on Evaluation Item 3, 4, and 6 (TS vs Xp)

	cellous condensation	spot welds	stress shielding	
	TS	TS	Xp	TS
zone 1	○ (12w/6m)	—	○ (6m)	—
zone 3	○ (12w/6m)	—	—	—
zone 5	○ (6m)	—	—	—
zone 6	○ (12w/6m)	○ (6m)	—	—
zone 7	—	—	—	○ (6m)

The results of other findings were as follows.

- 2 weeks after surgery: No findings on both Xp and TS images
- 1 (Reactive line): Not Statistically Significant (NS)
- 2 (Radiolucent line): NS
- 5 (Cortical hypertrophy): NS
- 7 (Subsidence: 2 mm or greater): 1 joint
- 8 (Pedestal formation): No findings
- 9 (Occult fracture): No findings

Observed findings other than the above 9 evaluation items were as follows.

- Comparison by shape of the femoral canal: NS
- Comparison by stem shape/surface finish: NS
- By stem alignment: See the table below.

Table 3 Comparison by Stem Alignment (Intermediate group vs Varus group)

	radiolucent line	cellous condensation	cortical hypertrophy		stress shielding	
	TS	TS	Xp	TS	Xp	TS
zone 1	○ (12w/6m)	—	—	—	○ (6m)	○ (12w)
zone 2	—	○ (6m)	○ (6m)	○ (6m)	—	—
zone 3	—	—	○ (6m)	○ (6m)	—	—

4. Discussion

TS imaging is performed by moving the X-ray tube and flat panel detector (FPD) parallel to each other in opposing directions. Using an image reconstruction technique called filtered back projection (FBP), TS images of required regions are reconstructed with the multiple projection images by a single X-ray exposure. The characteristics of TS are summarized in Table 4.

Table 4 Characteristics of TS (Compared with Tomography and CT)

	TS	Tomography	CT
Imaging Time	Short	Depends on number of exposures	Short
Radiation dose	Low (approx. twice that of Xp)	Moderate	High
Spatial Resolution	High	Fairly low	High
Metal Artifacts	Few	Few	Many
Patient posture	No restrictions	No restrictions	Restricted

Pellegrini et al. stated about biological fixation that spot welds became clearly visible around the porous surface from 1.5 years or later after surgery on Xp images.¹⁾ Meanwhile, Coathup et al. confirmed that the bone ingrowth on the porous surface was present as histological findings with retrieved THA components within 6 months after surgery.²⁾

We compared Xp with TS, which provides better spatial resolution than Xp. On performing both imaging modalities 2 weeks, 12 weeks, and 6 months after surgery, the detection rate of biological fixation was significantly higher using TS. TS can provide more accurate status of osseointegration between cementless stem and bone at an earlier stage compared to Xp, and is considered an effective method for evaluating biological fixation.

Limitations of this research include the small number of subjects, the high likelihood of bias in stem model use, and only frontal view TS images were evaluated. Bone-preserving stems such as taper wedge stems have a larger porous surface area on their anterior and posterior surfaces than on their medial and lateral surfaces, so more bone trabeculae can be visualized using a lateral view rather than a frontal view. Future research should evaluate early biological fixation with lateral view TS images for various types of femoral stem.

5. Conclusions

- TS and Xp images were compared to investigate the validity of using TS to evaluate early biological fixation between cementless stems and femur.
- TS was more useful than Xp in the early evaluation of intramedullary changes in cancellous bone around the stem, such as spot welds and cancellous condensation.
- TS was considered more useful imaging modality than Xp for evaluating the status of early biological fixation of cementless stem and femur.

References

- 1) Pellegrini V.D., et al JBJS Br. 74, 814 ~ 821; 1992
- 2) Coathup M.J., et al JBJS Br. 83, 118 ~ 123 ; 2001