

# The Detection of Radiolucent Line in Total Knee Arthroplasty Using of Tomosynthesis

Department of Orthopaedic Surgery, Faculty of Medicine, Saga University

Satomi Nagamine, Shuya Ide, Tomonori Tajima, Shinsuke Someya, Motoki Sonohata, and Masaaki Mawatari

## 1. Introduction

T-smart, being developed as the tomosynthesis providing tomographic images with few metal artifacts, is considered useful for the postoperative evaluation of total knee arthroplasty (TKA) due to its capacity for detecting minute changes in periprosthetic bone. We compared radiography and tomosynthesis images obtained after TKA, and investigated the usefulness of tomosynthesis for the early stage biological fixation.

- (1) Radiography images and tomosynthesis images were obtained 6 months after surgery, and the rate of emergence of periprosthetic radiolucent lines (RLLs) were determined. The emergence of a gap of 0.5 mm or more was defined as positive.
- (2) The proportion of appropriate and evaluable frontal radiography of the tibia and lateral radiography of the femur was determined.

The segmented zones of each radiography are shown in Fig. 1. The X-ray system used was a Shimadzu SONIALVISION series R/F system.

## 2. Subjects and Methods

Subjects included 47 knees among 30 patients (bilateral simultaneous TKA in 17 patients and unilateral TKA in 13 patients) who underwent cemented posterior-stabilized TKA with the Persona (Zimmer Biomet) for the medial knee osteoarthritis between April 2014 and March 2015. The mean age at time of surgery was 77.7 years (66 to 86 years).

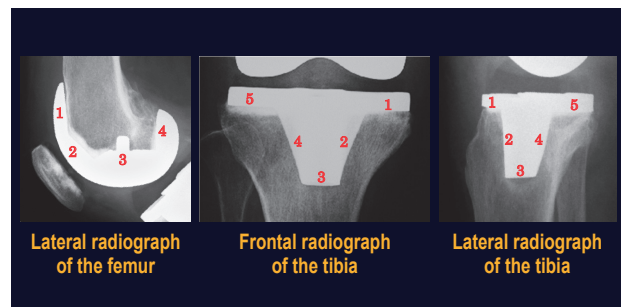


Fig.1

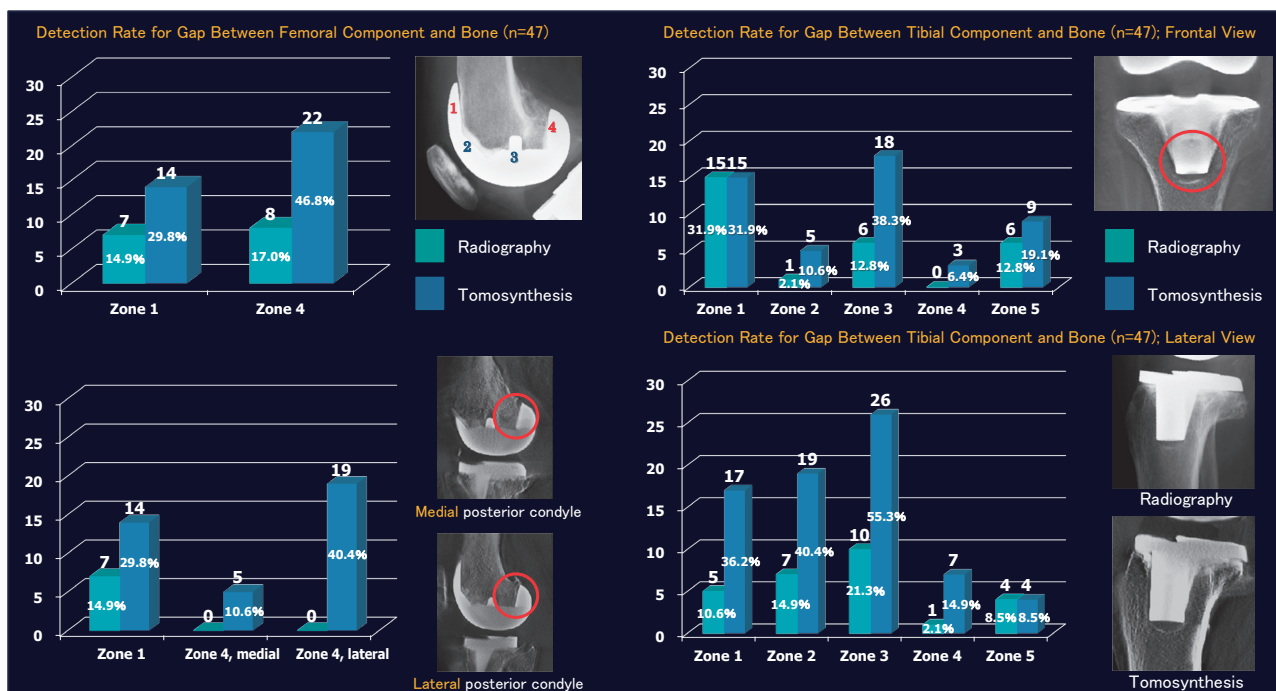


Fig.2

### 3. Results

A result of investigation (1) is shown in Fig. 2. The red numbers indicate radiolucent zones and the red circles show areas of note.

As a result of investigation (2), the appropriate and evaluable frontal images of the tibial component, and the lateral images of the femoral component were obtained by radiography in 57.4 %, and 46.8 % respectively (Fig. 3).

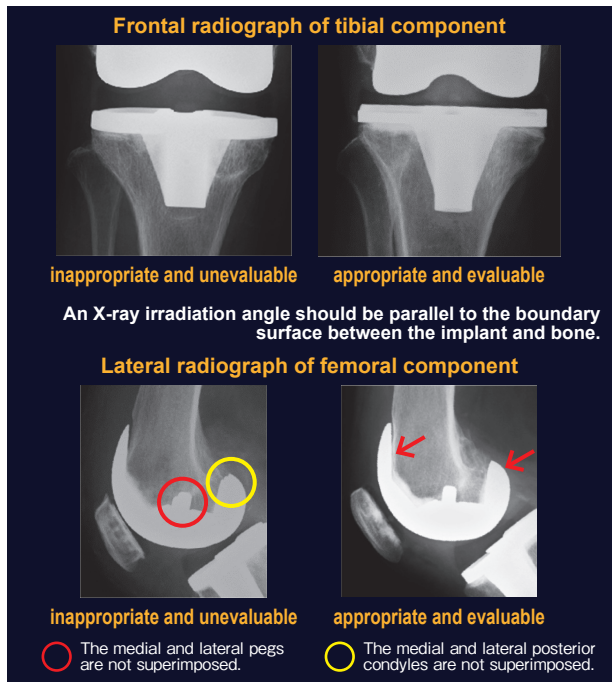


Fig.3

### 4. Discussion

RLLs are evaluated accurately by fluoroscopy guided radiography 1 week after TKA at our hospital. The radiological technologists are instructed that an X-ray irradiation angle should be accurately parallel to the component/bone boundary plane. Frontal radiographs require accurate alignment with the boundary plane between the tibial component

**[Characteristics of Tomosynthesis]**

- Tomosynthesis images are evaluable and accurate since a large number of cross-sectional images parallel to the R/F table top are obtained in a single acquisition.
- Changes at the periprosthetic bone can be observed in the earlier stage by tomosynthesis because the effects of metal artifacts are minimal.

**[Issues of Tomosynthesis]**

- Although tomosynthesis reduces metal artifacts, they are not prevented entirely, and image quality will alter depending on such as imaging conditions.
- The RLL detection rate with tomosynthesis is higher than the actual RLL emergence rate.

- ✓ Radiolucent line
- ✓ Reactive line
- ✓ Initial gap (anteromedial gap in grand-piano sign, initial gap of patella groove, etc.)
- ✓ Artifact gap (alters depending on X-ray parameters, materials of prostheses, patient postures, scanning directions, and component designs)

↓

All the above phenomena are evaluated as RLL positive.

Fig.4

and bone, and lateral radiographs require accurate alignment with the boundary plane between the femoral component and bone, though there are limitations in conventional radiography.

While a variety of refinements are implemented when performing tomosynthesis at our hospital, the two practices shown in Fig. 5 are considered particularly important.

**Practice 1: Accurate Measurements**

Accurately measured values should be entered for the height of the central imaging position and the thickness of the subject.

**Practice 2: Scanning Along Transverse Axis**

Frontal view    Lateral view      Frontal view    Lateral view

Scanning along transverse axis      Scanning along longitudinal axis

Metal artifacts are minimized when the scanning is performed along the transverse axis compared to the longitudinal axis.

Fig.5

### 5. Conclusions

- Tomosynthesis was able to visualize periprosthetic bone accurately that was difficult to evaluate with radiography. Furthermore, with T-smart processing that reduces metal artifacts, tomosynthesis could be used for early detection of periprosthetic minute changes of bone.
- Lateral tomosynthesis could be used to evaluate the medial and lateral posterior condyle of the femur separately.
- Metal artifacts in tomosynthesis images altered based on factors such as X-ray parameters, materials of prostheses, patient postures, and scanning directions. And tomosynthesis required refinement of the imaging methods and imaging condition settings.
- The scanning along the transverse axis were effective for both the periprosthetic tibia and femur tomosynthesis.