

# Clinical utility of T-smart tomosynthesis for micro MAX stem total hip arthroplasty

Department of Orthopedic Surgery, Kainan Hospital<sup>1</sup>, Department of Arthroplastic Medicine, Nagoya City University<sup>2</sup>  
Yoshihiro Shibata<sup>1</sup>, Isato Sekiya<sup>1</sup>, Naoya Takada<sup>1</sup>, Yuka Mukofujiwara<sup>1</sup>, Yoshikazu Hayashi<sup>1</sup>,  
Yasuhiro Katsuda<sup>1</sup>, Akira Kondo<sup>1</sup>, and Hirotaka Iguchi<sup>2</sup>

## 1. Purpose

The Revelation microMAX stem (**Fig. 1**) is a cementless short stem with a lateral flare design that allows for proximal physiological load transmission. T-smart (Tomosynthesis-Shimadzu Metal Artifact Reduction Technology) tomosynthesis reduces artifacts near metal objects and enable clearer visualization of the peri-implant trabecular structure, which provide beneficial images for confirming implant fixation status. We believe that T-smart tomosynthesis is useful for estimating the condition of microMAX stem fixation and hereby report on observation of the postoperative course of microMAX stem.

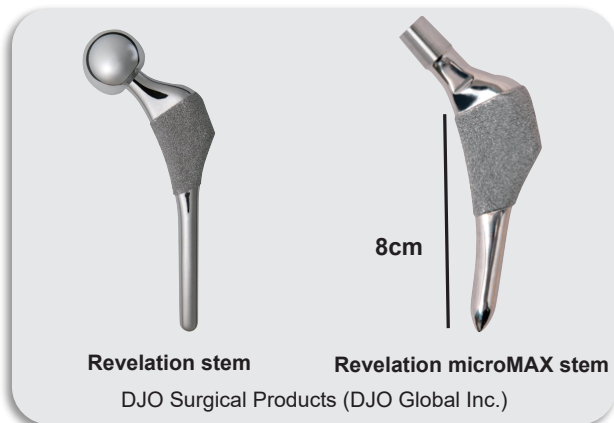


Fig.1

## 2. Materials and Methods

Subjects comprised 19 patients (20 hips) who underwent THA using microMAX stem between July 2012 and November 2014. The subjects included 7 males and 12 females with a mean age of 67 (ranging from 38 to 83 years). Four patients had femoral head necrosis and 15 patients had osteoarthritis of the hip. The mean duration of follow-up is 16.4 months (ranging from 3 to 33 months).

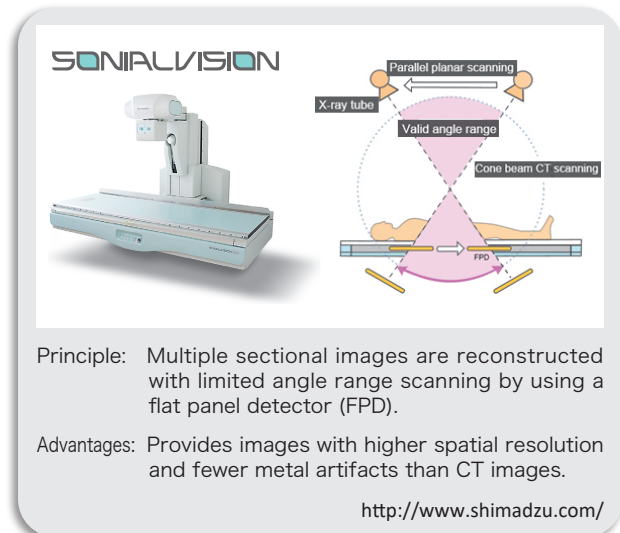


Fig.2

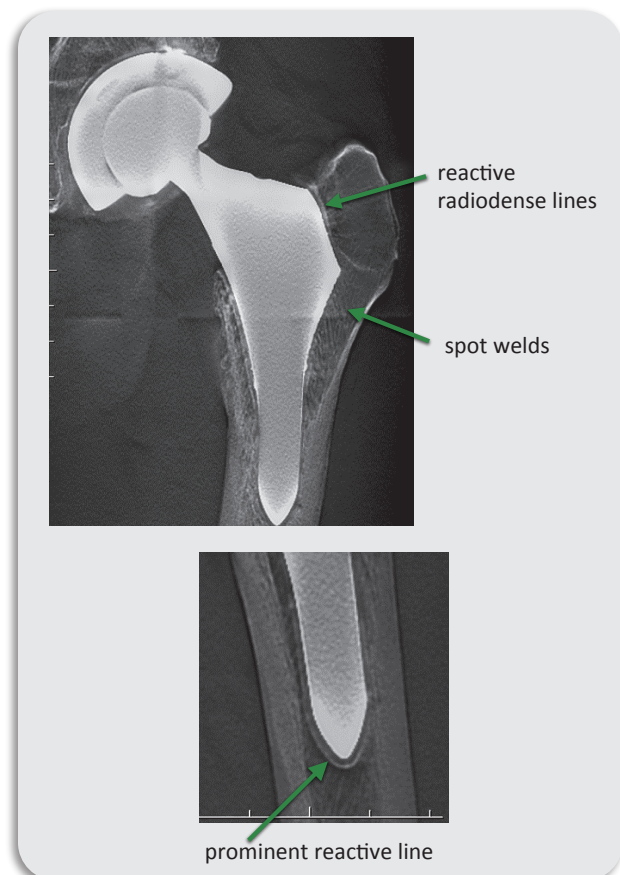


Fig.3

Based on X-ray and T-smart tomosynthesis images (Fig. 2) obtained for all cases to determine the incidence and distribution of spot welds, and the incidence of reactive radiodense lines and prominent reactive lines (Fig. 3).

### 3. Results

The incidence and distribution of spot welds and the incidence of reactive radiodense lines and prominent reactive lines in X-ray and T-smart tomosynthesis images are shown in Fig.4. No stem loosening was noted in any of the cases.

### 4. Discussion

Because tomosynthesis provides higher spatial resolution sectional images than CT, the utility of tomosynthesis for orthopedic applications has been reported. Furthermore, periprosthetic metal artifacts can be reduced even further by using T-smart, a new method involving iterative reconstruction. Consequently, the status of periprosthetic bone can be observed in fine detail. However, it also has

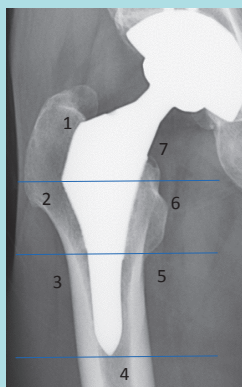
the characteristic of decreasing spatial resolution in sectional images as the distance from the center height (off-focus planes) increases. Therefore, the imaging direction, the center height and the image reconstruction parameters must be appropriately specified to obtain an optimized image quality.

For the cases we observed, we were able to confirm periprosthetic changes of the stem in more detail using T-smart tomosynthesis than with X-ray images, and we were able to confirm the postoperative stability of the Revelation microMAX stem and its proximal load transmission. Though cementless short stems offer many advantages, they involve some instability in initial fixation. Therefore, T-smart tomosynthesis, which enables detailed observation of the early stage postoperative peri-implant trabeculae, is especially useful for determining the status of load transmission and implant fixation.

### 5. Conclusion

Tomosynthesis was used to evaluate the postoperative course of microMAX stem. T-smart tomosynthesis was useful for determining the status of load transmission and implant fixation.

Results: No stem loosening was noted in any of the cases.



	X-ray	T-smart tomosynthesis
spot welds	12 hips (60%)	19 hips (95%)
reactive radiodense lines	8 hips (40%)	10 hips (50%)
prominent reactive line	3 hips (15%)	4 hips (20%)

Distribution of Spot welds

Zone	1	2	3	4	5	6
X-ray	0	10	2	0	0	8
T-smart tomosynthesis	0	17	4	0	0	15

Fig.4