

Surgery

Our Experience Using LIGHTVISION for Lymphaticovenular Anastomosis



Akitatsu Hayashi, M.D.

Lymphedema Clinic, Department of Breast Center, Kameda Medical Center

Lymphedema Clinic, Kameda Kyobashi Clinic

Akitatsu Hayashi

1. Introduction

Kameda Medical Center boasts 380 years of history, 35 medical departments, and about 3,000 staff, and is a foundation hospital located in southern Chiba Prefecture that focuses mainly on providing acute phase advanced medical care (**Fig. 1**). In 1995, Kameda Medical Center was the first facility in the world to implement a full-scale electronic medical record system and is known as one of the rare facilities in Japan that implements total information utilization for medical care. We are also fully committed to improving our quality of medical care, with all medical services, including the clinical section, ISO 9001 accredited and certified by the Japan Council for Quality Health Care. Furthermore, in 2009, we were the first facility in Japan to receive accreditation from the Joint Commission International (JCI) that evaluates health care systems and practices. Started in April 2013, the Kyobashi Clinic in Tokyo has also established a women's clinic and medical checkup facilities and provides medical care to foreigners and patients from Tokyo and throughout Japan.

In February 2018, our department of breast center started a lymphedema clinic to meet an increased demand for treatment of secondary lymphedema

arising after surgery, radiotherapy, and chemotherapy for breast cancer. Until establishing the lymphedema clinic, our only option for treating lymphedema was to start conservative therapy once arms and legs had already become swollen. Now, a lymphedema specialist carries out examinations and imaging investigations for early discovery and treatment of lymphedema, and surgical treatment is also available for indicated patients. Typical surgical treatments for lymphedema include lymphaticovenular anastomosis and vascularized lymph node/vessel transplantation. Indocyanine green (ICG) plays a key role in all these surgeries for both preoperative and perioperative lymphography. ICG lymphography, or ICG fluorescence imaging, is a technique that allows observation of lymphatic vessels by irradiating ICG taken up by lymphatic vessels with near-infrared excitation light, which is visualized as near-infrared fluorescence emitted by ICG. The near-infrared camera system used by this technique can be arm-mounted or hand-held depending on the retention system, and in 2016, Shimadzu developed an arm-mounted LIGHTVISION near-infrared fluorescence imaging system that displays detailed high definition images. LIGHTVISION has been used at our facility since the spring of 2018 in over 100 cases and for over 300 lymphaticovenular anastomosis procedures. Here we report on our experience using Shimadzu's LIGHTVISION system.



Fig.1

2. What is Lymphaticovenular Anastomosis for Lymphedema?

Lymphatic vessels in the extremities normally follow an independent route until emptying into the left and right subclavian veins. However, in cases of secondary lymphedema following cancer surgery, there is gradual and progressive lymphatic vessel degeneration (**Fig. 2**) that causes lymphedema when lymph fluid flow is blocked at some point in

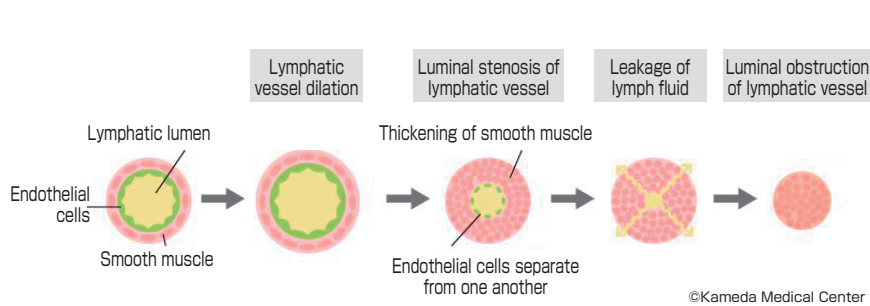


Fig.2

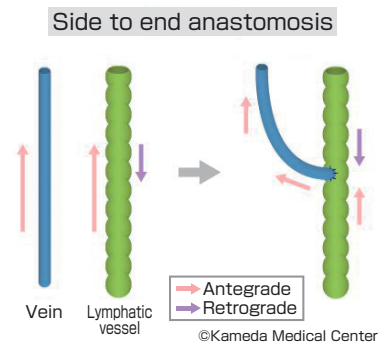


Fig.3

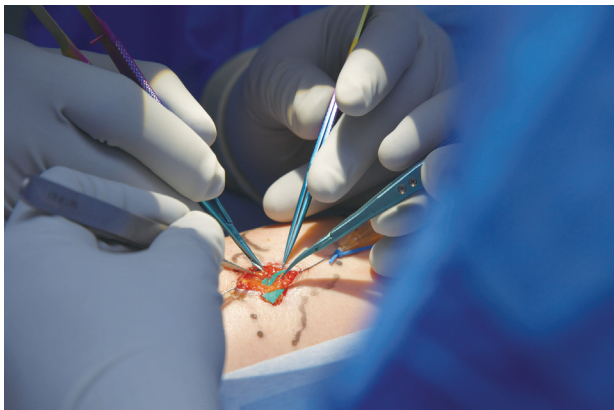


Fig.4

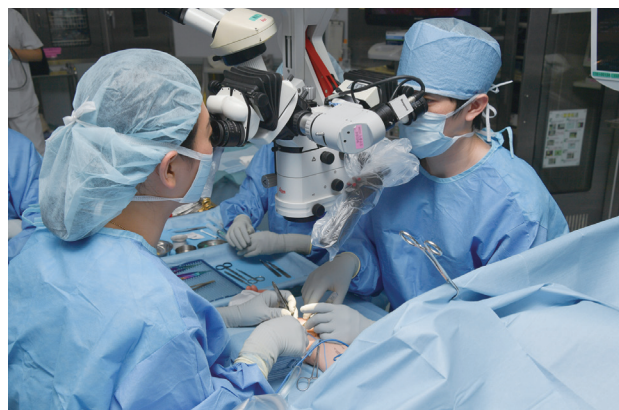

Fig.5

the vessel. Lymphaticovenular anastomosis is a functional reconstructive surgery that bypasses the lymph blockage and resolves lymph fluid stasis by redirecting lymph flow into the vein from a point in the lymphatic vessel distal to the blockage (Fig. 3). The major technical challenge faced by this surgery was the extreme thinness of lymphatic vessels in the extremities (internal diameter of 0.2–1.0 mm), but recent improvements in surgical tools and techniques, such as forceps and threads designed for 50 μm ultra-fine vessel anastomosis (Fig. 4), have resulted in the emergence of “supermicrosurgery” that can perform proper anastomosis of vessels under 0.5 mm diameter and has led to the development and evolution of lymphaticovenular anastomosis (LVA) in Japan, which is a procedure that performs anastomosis of the lymphatic vessel and venule endothelium. Progress has been made in reducing the risk of obstruction and thrombus formation at the anastomotic site and improving surgical outcomes for LVA, and interest in this surgery is currently spreading throughout the world due to the low invasiveness and the effectiveness of the procedure.

3. ICG Fluorescence Imaging in Lymphaticovenular Anastomosis

Preanastomosis lymphatic vessel selection is directly linked to success or failure of surgery and is, therefore, the most important step in LVA, and is where ICG fluorescence imaging comes into its own. ICG fluorescence imaging can visualize the flow dynamics of lymph fluid in lymphatic vessels and is one of the best methods we currently have for identifying lymphatic vessels for LVA. When lymphatic vessels appear as a linear pattern on ICG fluorescence imaging, it shows the visualized region of the vessel is still actively transporting lymph fluid. The ability to identify such lymphatic vessels with active flow during surgery is important, regardless of lymphedema severity. Lymphatic vessels with active flow have undergone relatively little degeneration, are often easy to anastomotize, and tend to result in effective LVA. However, even after a linear pattern is verified following an initial injection of ICG, in patients with moderate or more severe lymphedema the region of lymph congestion can spread over time, creating dermal backflow patterns that obscure the linear patterns. In these situations, the identification of functional lymphatic vessel during surgery with ICG fluorescence

imaging becomes even more important.

In addition, stenosis at the site of anastomosis is also more common with supermicrosurgery than normal microsurgery, as supermicrosurgery performs anastomosis on vessels 0.5 mm and smaller in size. For these reasons, ICG fluorescence imaging is also important for evaluating surgery immediately after anastomosis to verify outflow into the anastomotized vein. Weak outflow or no outflow of ICG into the vein at this time indicates the anastomosis site is at high risk of obstruction and reanastomosis must be considered.

As such, ICG fluorescence imaging plays an extremely important role in lymphaticovenular anastomosis. At this hospital, after consent has been obtained from the patient, ICG fluorescence imaging is always used as part of lymphaticovenular anastomosis.

4. Characteristic Features of LIGHTVISION and Utility in Lymphaticovenular Anastomosis

First of all, LIGHTVISION is easy to use and easy to manipulate in surgery. The camera arm can be folded away during transit, extended during use, and allows free adjustment of the camera position. The camera arm extends up to around 180 cm and rotates horizontally through an angle of around 40 degrees, allowing the main unit to be positioned away from the operative field to ensure a wide range of movement around the patient and allow large microscopes used in surgeries like LVA to be positioned safely and with flexibility (Fig. 6). The main unit is also equipped with a small display monitor and remote control so the operator can verify control and perform image quality adjustments, and allows the surgeon and operator to share images and continue with surgery without stress. Another major feature of LIGHTVISION is that imaging can be performed in an illuminated operating

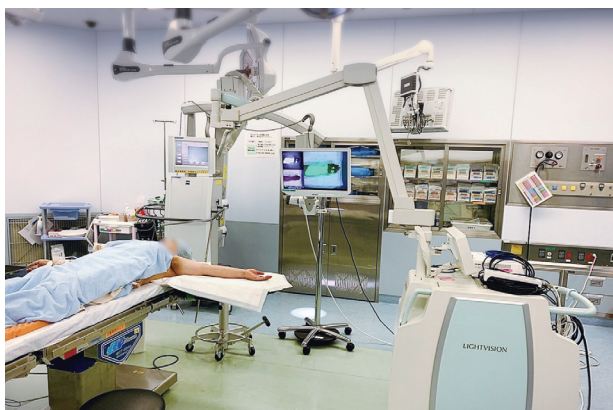

Fig.6

room allowing surgery to proceed in comfort and without stress.

One more major feature of this system is the simultaneous three-window display and display switching function. Visible light images, near-infrared images, and visible light + near-infrared images acquired by the image sensor can be shown simultaneously on the three-window display to allow verification and comparison of each image at a glance, even during surgery. For example, when three lymphatic vessels are within the field of view, the three-window display allows immediate determination of which lymphatic vessel is functional and the location of the functional lymphatic vessel without the need to switch between image views or compare with a microscope field of view (Fig. 7). The image displayed in the largest window can also be changed easily, and our surgeons are pleased with the ability to quickly view the images they need to (Fig. 8, 9).

Finally, I would like to mention the safety of the system. Although this system operates at a camera-to-subject distance of 500–700 mm, the system is equipped with a strong zoom function and displays very detailed, high definition images that can verify flow in even very fine lymphatic vessels of 0.2 mm or smaller diameter. Compared to microscope platforms capable of fluorescence imaging that are often used in lymphatic surgery, we found lymphatic vessels were identified clearly by LIGHTVISION in 12 cases that the microscope platform either failed to identify or identified only poorly. While it is convenient to have fluoroscopic imaging functions on a microscope, the short distance between the microscope and subject presents a constant risk of burning or damaging skin or tissue that is a constant concern for the surgeon. LIGHTVISION allows for safer and more accurate identification of lymphatic vessels and evaluation of anastomosis sites.

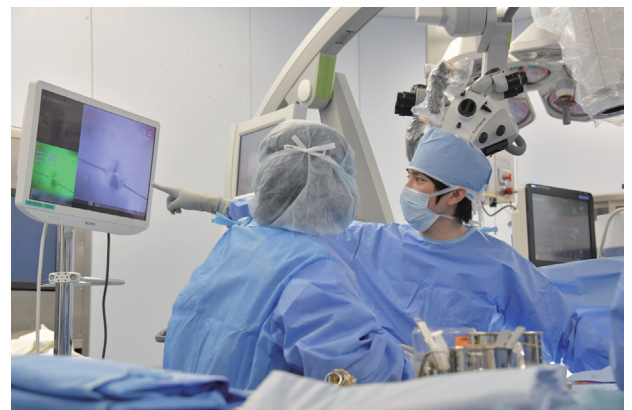

Fig.7

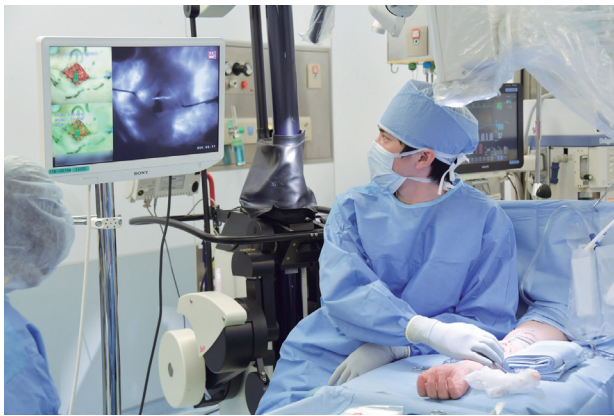

Fig.8

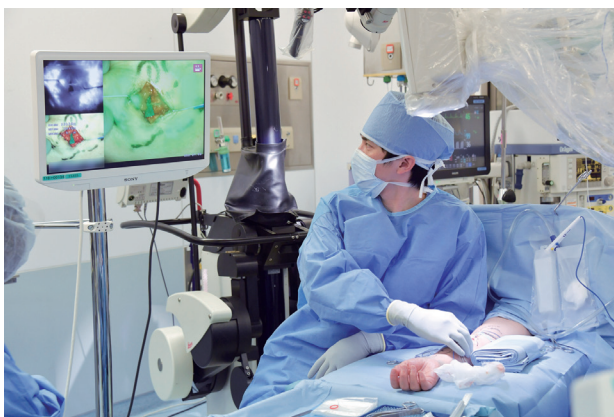

Fig.9

5. Conclusion

The use of lymphaticovenular anastomosis for lymphedema following cancer surgery has spread widely in the last few years. In this time, we have learned that lymphatic vessel selection before anastomosis has a major effect on postoperative outcomes. We think that LIGHTVISION, which allows for safe and highly accurate lymphatic vessel selection and evaluation after anastomosis, is extremely useful for either facilities that use microscopes equipped with fluorescence imaging functions, or in facilities that only have normal microscopes. Of the near-infrared fluorescence camera systems, LIGHTVISION is the only system that produces color images in high definition and we expect LIGHTVISION to become an indispensable tool in lymphedema surgery.

References

- 1) Koshima I, Inagawa K, Urushibara K, Moriguchi T. Supermicrosurgical lymphaticovenular anastomosis for the treatment of lymphedema in the upper extremities. *J Reconstr Microsurg.* 2000;16:437-442.
- 2) Yamamoto T, Yamamoto N, Yoshimatsu H, et al. Factors Associated with Lymphosclerosis: An Analysis on 962 Lymphatic Vessels. *Plast Reconstr Surg.* 2017;140:734-741.
- 3) Hayashi A, Hayashi N, Yoshimatsu H, et al. Effective and efficient lymphaticovenular anastomosis using preoperative ultrasound detection technique of lymphatic vessels in lower extremity lymphedema. *J Surg Oncol.* 2018 Feb; 117 (2):290-298