

RAD

Experience Using RADspeed Pro for Dynamic Radiography



Koji Yamashita, R.T.

Department of Radiology, Kyorin University Hospital
Koji Yamashita

1. Introducing the Hospital

Located in Mitaka City, Tokyo, Kyorin University Hospital is an “advanced treatment hospital” providing advanced medical care, an “advanced emergency and critical care center” operating on a 24-hour basis, is the only university hospital in the Tama region, and has 1,153 beds and 64 radiological technologists. Kyorin University Hospital is a core hospital in the Tama area, a large region that comprises the western half of Tokyo and contains one-third of the population of the Tokyo Metropolis. The hospital is responsible for providing medical care not only in the Tama area but also in the western Wards of Tokyo, including neighboring Setagaya and Suginami Cities (Fig. 1).



Fig.1 View of Kyorin University Hospital

2. System Setup and Characteristic Features of Radiography Room

In June 2020, the hospital procured a Shimadzu RADspeed Pro digital general radiography system (hereinafter, “RADspeed Pro”) alongside a Konica Minolta AeroDR fine digital radiography system during renovations to the radiography room and started to perform dynamic chest radiography in clinical practice (Fig. 2). The radiography room is

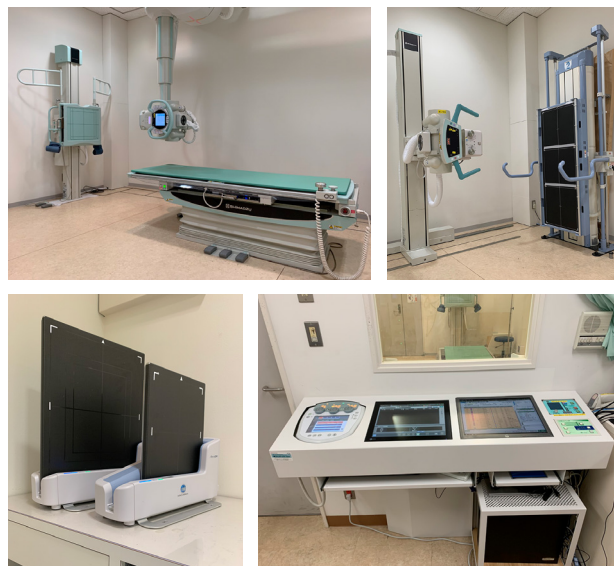

Fig.2 RADspeed Pro System

a multipurpose space in which a system must offer high levels of imaging accuracy and also versatility, and perform not just dynamic radiography, but imaging of all parts of the body in various patient positions. In terms of imaging modalities other than dynamic radiography, RADspeed Pro integrates a combination of equipment, functions, and applications and flexibly meets the various needs of the hospital.

3. Setup and Features of Dynamic Radiography System

The dynamic radiography system uses an X-ray generator capable of sequential pulse irradiation and a flat panel detector (FPD) that supports dynamic imaging. The system also supports imaging in various body positions, including standing, sitting, and supine positions. Conventionally, chest radiography has only acquired static images that offer partial insights such as images during the maximal inspiration phase or maximal expiration phase, but dynamic radiography can acquire sequential data during respiratory movement

that spans from maximal inspiration to maximal expiration. Images are acquired on an FPD with a 400 × 400 μm pixel pitch, 16-bit depth, and image area of 17 × 17 inch (42.5 × 42.5 cm) allowing imaging of a variety of large and small sites in the chest, neck, and extremities. The X-ray generator can also be set to generate sequentially pulsed X-rays with irradiation times of any duration up to 20 seconds. The only frame rate available when RADspeed Pro was first procured was 15 frames per second (fps), but 6 fps can also be used today. By suitably combining these irradiation times and frame rates, we can perform dynamic radiography of various sites of interest in respiratory, cardiovascular, and orthopedic areas with due consideration to radiation doses (Fig. 3). As post-image processing, we use the image processing technology in Konica Minolta's KINOSIS dynamic image analysis workstation (not RADspeed Pro) to visualize structures in the chest area, automatically calculate the lung area,

quantitatively evaluate diaphragm movement, and visualize function in the respiratory and cardiovascular regions (Fig. 4).

4. Dynamic Radiography Techniques in Kyorin University Hospital

At our hospital, requests for dynamic chest radiography are mostly received from the department of respiratory medicine, department of respiratory surgery, department of cardiology, department of thyroid surgery, and department of radiology, and routine dynamic radiography procedures have been established and are followed for each requesting department. For dynamic chest radiography, we acquire original images that combine three to five different image processing steps applied to each imaging protocol, including breath-hold, forced respiration, and dynamic neck radiography (Table 1).

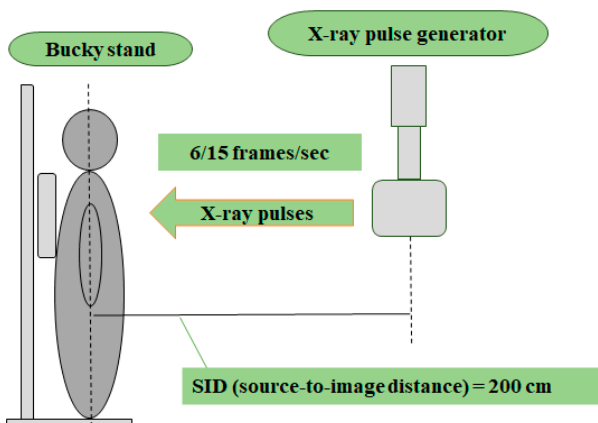


Fig.3 Dynamic Radiography System Setup

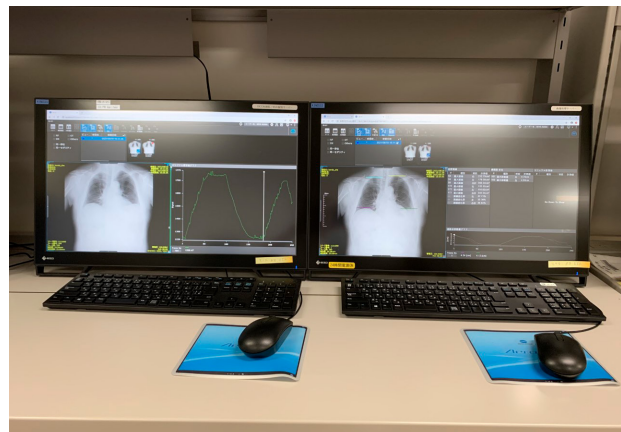


Fig.4 KINOSIS

Table 1 Dynamic Radiography by Department

Requesting Department	Department of Respiratory Surgery			Department of Respiratory Medicine	Department of Cardiology	Radiation therapy	Department of Thyroid Surgery
Clinical Diagnosis	Pneumothorax	Other	Mediastinum	All cases	All cases		Thyroid/vocal cord area
Imaging Protocol	PL: Deep breathing	PH: Breath-hold + PL: Deep breathing	PL: Deep breathing (Standing + Supine)	PH: Breath-hold + PL: Deep breathing	PL (Standing + Supine)		Vocal cords A: Enunciation → P PL
X-ray techniques	Small		80mA		80mA		90kV 200mA 2.5msec
	Large		200mA		100kV 125mA 4.0msec		
Source-to-Image Distance	200cm (40/12 : 1)			150cm (40/10 : 1)		150cm (40/8 : 1)	
Voice Instruction System	PH: Each breath-hold (7 seconds) PL: Respiratory region (Voice (1))				As per PL	Natural breathing (around 10 seconds)	Thyroid (English-Voice (4))
Image Processing	PL (Original · PL · FE · BS · BsXFE)			PL (Original · FE)	Original	Original	Original + FE (Enlarge and send)
	Before Ope :PH2+LM After Ope :PH2		+				

During dynamic chest radiography, breath-hold imaging is performed for approx. 7 seconds in a standing or supine position, and a voice instruction system is utilized in forced respiration imaging for approx. 14 seconds, which includes maximal inspiratory position, expiratory phase, maximal expiratory position, and inspiratory phase imaging. Patients are provided instructions in order to prevent disparities arising due to patient motion and differences in breathing, and examinations are performed as the patient performs breathing exercises that follow the directions of the voice instruction system as close as possible (Fig. 5).

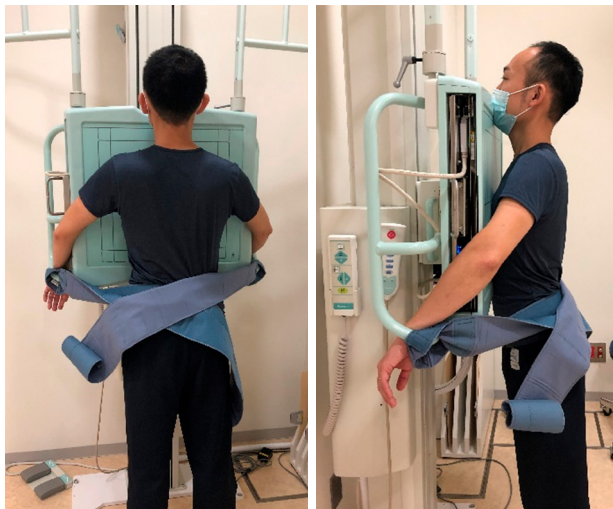

Fig.5 Positioning for Dynamic Chest Radiography

Patients are seated during dynamic neck radiography to limit body movement and ensure examination reproducibility. The patient's mandible is elevated and the head immobilized so radiography is performed with the anthropological baseline at 25 degrees to the FPD. A total imaging time of approx. 7 seconds includes both breathing and vocalization, and patients are instructed to maintain a steady tone during vocalization due to the impact of unstable tones on vocal cord movement (Fig. 6).

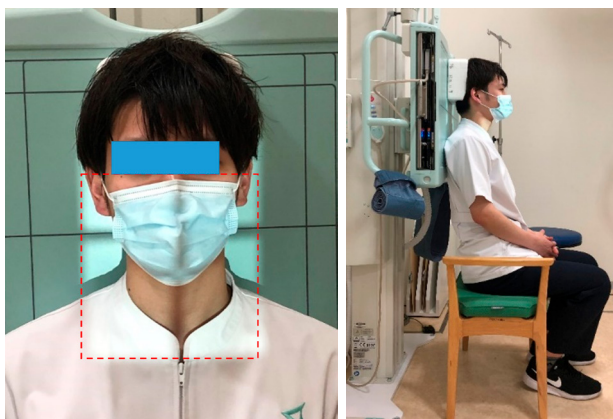

Fig.6 Positioning for Dynamic Neck Radiography

Upon acquisition, dynamic images are analyzed automatically by KINOSIS to create images that display quantitative data and functional information. The different types of image processing available are frequency enhanced processing (FE-MODE) that enhances specific frequency bands; bone suppression processing (BS-MODE) that reduces signals from the ribs and clavicle area within the lung field; diaphragm motion processing (DM-MODE) that performs specific component tracking to measure maximum and minimum lung field area, change, and diaphragm movement; pixel value change-low frequency processing (PL-MODE) that performs reference frame ratio processing to enhance and visualize breathing-associated signal changes in lung field tissue (changes in X-ray transmission); and pixel value change-high frequency processing (PH-MODE) that visualizes signal changes related to the heartbeat in lung field tissue when imaging a breath-hold for 7 seconds (Fig. 7).

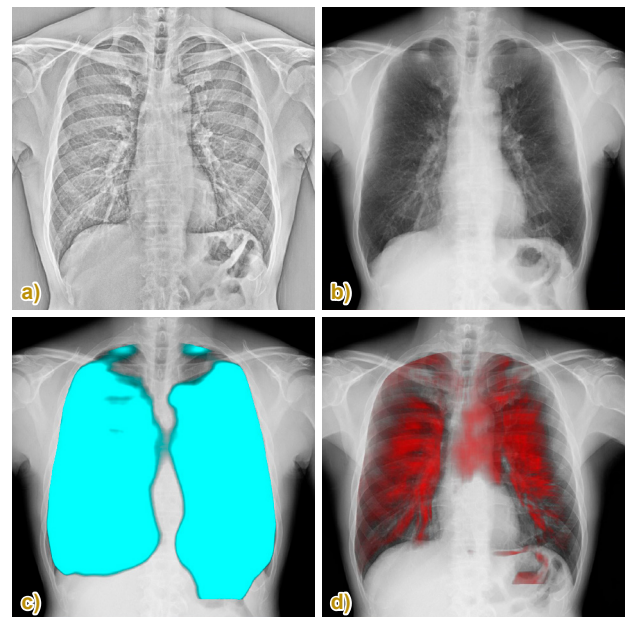


Fig.7 a) FE-MODE
b) BS-MODE
c) PL-MODE
d) PH-MODE

The maximum size of dynamic image files sent for viewing by physicians, including processed images, is around 5 GB. Based on the number of images acquired, this is equivalent to approx. 30 % of the total file size of all hospital images transferred in 1 month. Although the sequential images acquired by dynamic radiography make it a clinically useful technique, the nature of these sequential images makes the image file sizes much larger than static images. As well as a main server dedicated to viewing dynamic images, many facilities also install client terminals in each department.

Our hospital does not send all images to the main PACS server because server capacity would become overwhelmed. Since images could not be viewed in departments where there are no client terminals, the hospital built a viewing environment that utilizes a general image viewing system. By linking this viewing system to all dynamic images, the system can be used to instantaneously view dynamic images and images processed by KINOSIS from approx. 2.000 medical record systems held at our hospital (Fig. 8).

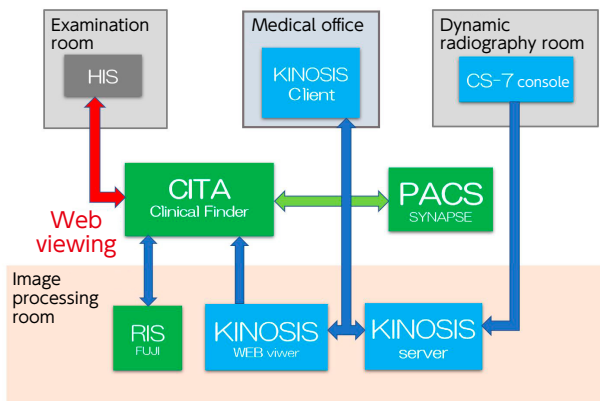


Fig.8 Network Diagram

5. Clinical Images

• Pneumothorax

Here is presented a case diagnosed with pneumothorax by dynamic chest radiography.

Determining pulmonary collapse, identifying blebs and bullae, and determining air leaks are important for pneumothorax diagnosis, and dynamic radiography can be used to evaluate the status of a collapsed lung based on associated respiratory motion and mediastinal shifts requiring urgent attention (Fig. 9). BS x FE-MODE image processing also improves the visibility of blebs and bullae that overlap costal shadows (Fig. 10).

• Bronchial Stenosis

Here is presented a case of right bronchial stenosis caused by lung cancer in which the airway was secured with a stent (Fig. 11). Breath-hold imaging was performed in addition to deep breathing imaging, revealing compression of pulmonary vessels and bronchi by a tumor at the hilus of the left lung, reduced signal levels in PH-MDOE and PL-MDOE in the left lung (Fig. 12), and left phrenic nerve paralysis and mediastinal shift (Fig. 13). Dynamic radiographs allow us to determine the effectiveness of treatment and check the course of recovery.

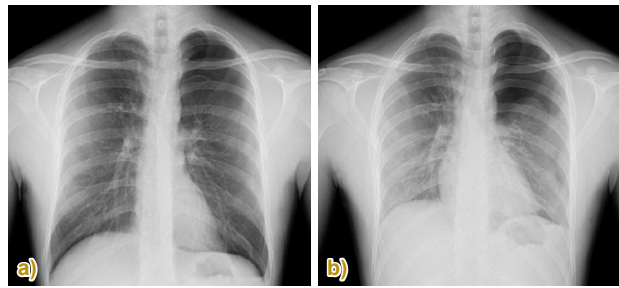


Fig.9 Pneumothorax Case
a) Original image at Maximal Inspiration
b) Original image at Expiration

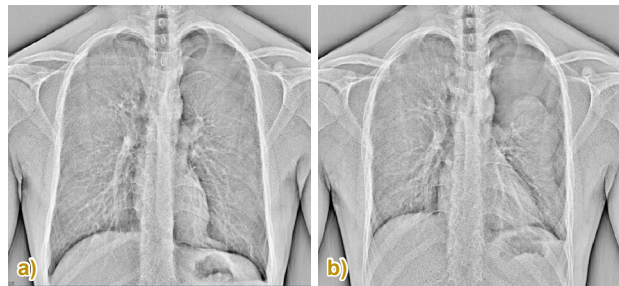

Fig.10 Pneumothorax Case
a) BS x FE-MODE at Maximal Inspiration
b) BS x FE-MODE at Expiration

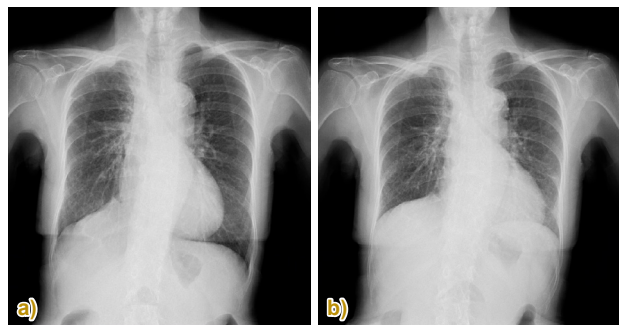


Fig.11 Right Bronchial Stenosis Case
a) Original image at Maximal Inspiration
b) Original image at Expiration

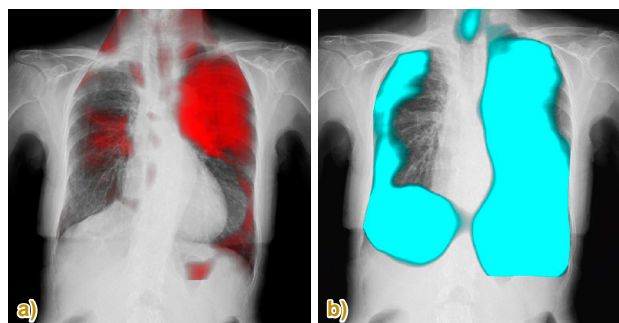


Fig.12 Right Bronchial Stenosis Case
a) PH-MODE b) PL-MODE

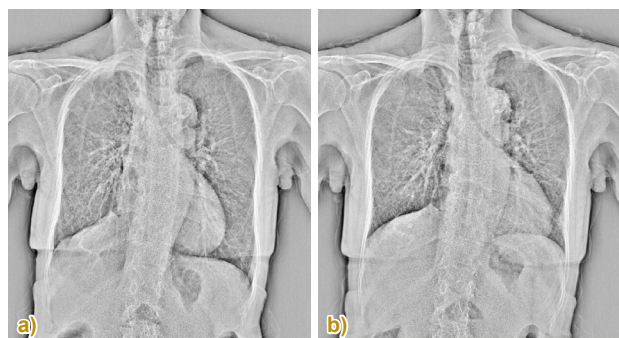

Fig.13 Right Bronchial Stenosis Case
a) BS x FE-MODE at Inspiration
b) BS x FE-MODE at Expiration

• Recurrent Nerve Paralysis

Here is presented a case of left recurrent nerve paralysis diagnosed by dynamic vocal cord radiography (Fig. 14, 15).

Dynamic neck radiography is used to examine the vocal cords. Recurrent nerve paralysis is normally diagnosed by laryngoscopy, but this procedure causes pain and places a significant physical burden on the patient, hence can only evaluate vocal cord movement in the upper part of the vocal cords. Dynamic radiography with deep breathing and vocalization offers a minimally invasive evaluation of the entire neck region and also allows us to extract minute vocal cord movements. Dynamic neck radiography is also useful in cases of post-surgical non-symptomatic transient recurrent nerve paralysis, including cases with hoarseness or dysphonia as a postoperative evaluation. Also, while laryngoscopy now carries the risk of COVID-19 transmission, dynamic radiography can be used to examine patients safely with no similar transmission risk.

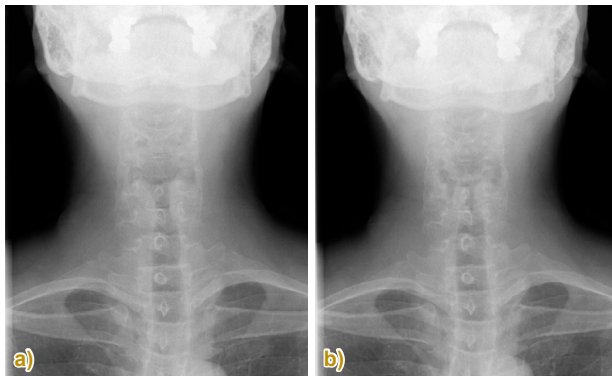


Fig.14 Recurrent Nerve Paralysis Case
a) Original image at Inspiration
b) Original image at Vocalization

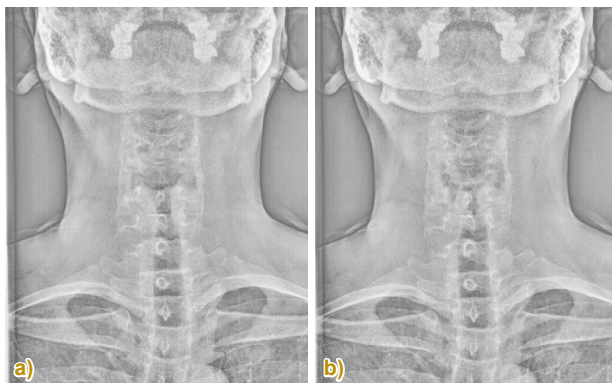


Fig.15 Recurrent Nerve Paralysis Case
a) FE-MODE at Inspiration
b) FE-MODE at Vocalization

6. Conclusion

Dynamic radiography can perform quantitative evaluation of diaphragm and chest movement in the thoracic region and acquire ventilation weighted images and blood flow weighted images without the use of contrast medium. Furthermore, dynamic radiography can acquire not only morphological information but also functional information through an examination that places a lower burden on the patient and poses a lower risk of disease transmission. For these reasons, dynamic radiography is expected to become a new reference in lung function testing. We look forward to dynamic radiography being developed to target more sites and disease indications, and more analytical tools being developed in tandem with this expansion. Finally, in the near future, we hope these techniques can be used not only to understand current pathologies but also to predict possible future pathologies, and will become established and widely adopted as a new imaging modality alongside existing general chest examinations.

References

- 1) Matsutani T.: Visualization and Quantitation of Physiological Function by Dynamic Radiography—Next Stage in Radiography—. JIRA Technical Report, 57:30-35, 2019.
- 2) Hashimoto N., et al.: Digital Dynamic Radiography: Technology and Clinical Applications. Journal of the Kyorin Medical Society, 52 (3):147-152, 2021.
- 3) Yamada Y, Ueyama M, Abe T, Araki T, Abe T, Nishino M, et al. Difference in diaphragmatic motion during tidal breathing in a standing position between COPD patients and normal subjects: time-resolved quantitative evaluation using dynamic chest radiography with flat panel detector system ("dynamic X-ray phrenicography"). European Journal of Radiology 87:76-82, 2017
- 4) Ohkura N, Kasahara K, Watanabe S, Miki A, Sone T, Hara J, Kimura H, Sanada S, Tanaka R. Evaluation of Pulmonary Function Using Dynamic Chest Radiographs: The Change Rate in Lung Area Due to Respiratory Motion Reflects Air Trapping in COPD. ATS Journals 197:A3893, 2018.
- 5) Sanada S. Physiologic-functional Radiography (pFRAD): dynamic imaging for physiological and functional diagnostic information. Journal of Wellness and Health Care 42 (4):1-8, 2018.

Unauthorized reproduction of this article is prohibited.